



# The 22<sup>nd</sup> Korea-China-Japan Pediatric Nephrology Seminar 2026

Date: **April 25**(Sat), 2026

Venue: Jeju Shinhwa World Hotel & Resort, Jeju, Korea

▶ Landing Convention Centre LGF, Landing Ballroom C





## Welcome Message



*Dear distinguished colleagues from Korea, China and Japan,*

It is a great honor and pleasure to welcome you all to the 22<sup>nd</sup> Korea-China-Japan Pediatric Nephrology Seminar, held here in the beautiful Jeju Island at Jeju Shinhwa World.

This seminar has long served as a valuable tradition where pediatric nephrologists from Korea, China, and Japan share knowledge, clinical experiences, and the latest research to advance the care of children with kidney diseases.

We are especially delighted to host this meeting in Korea this year, and we hope you will feel our warm hospitality throughout your stay.

Amid the pristine natural beauty of Jeju, we look forward to in-depth academic discussions and vibrant exchanges among participants.

We anticipate fruitful sessions where we can learn from one another's recent advancements and challenging clinical cases in pediatric nephrology.

May this seminar further strengthen the friendship and academic collaboration among our three countries.

We extend our deepest gratitude to all of you for your participation and commitment.


We wish everyone a highly successful and memorable meeting.

Thank you.

A handwritten signature in black ink, appearing to read 'Lee', written in a cursive style.

Joo Hoon Lee

President, Korean Society of Pediatric Nephrology



## Organization

### KOREA

Tae-Sun Ha	Chungbuk National University Hospital
Ji-Hong Kim	Gangnam Severance Hospital, Yonsei University,
Joo Hoon Lee	Asan Medical Center, Ulsan University
Hee Gyung Kang	Seoul National University Children's Hospital
Min Hyun Cho	Kyungpook National University Hospital (Liaison officer)
Heeyeon Cho	Samsung Medical Center, Sungkyunkwan University
Jae Il Shin	Severance Children's Hospital, Yonsei University
Kyoung Hee Han	Jeju National University Hospital
Eun mi Yang	Chonnam National University Hospital

### CHINA

Jie Ding	Peking University First Hospital
Xiaoyun Jiang	The First Affiliated Hospital of Sun Yat-sen University
Jianhua Mao	The Children's Hospital, Zhejiang University School of Medicine
Qiu Li	Children's Hospital of Chongqing Medical University
Qian Shen	Children's Hospital of Fudan University
Fang Wang	Peking University First Hospital
Suxia Wang	Peking University First Hospital
Zhengkun Xia	Jinling Hospital, Medical School of Nanjing University
Hong Xu	Children's Hospital of Fudan University
Zhuwen Yi	The Second Xiangya Hospital of Central South University
Aihua Zhang	Nanjing Children's Hospital
Xuhui Zhong	Peking University First Hospital (Liaison officer)
Jianhua Zhou	Tongji Hospital, Huazhong University of Science and Technology

**JAPAN**

Rika FUJIMARU	Division of Pediatric Endocrinology, Metabolism and Nephrology, Osaka City General Hospital
Kazumoto IJIMA	Department of Pediatrics, Kobe University Graduate School of Medicine
Kenji ISHIKURA	Department of Pediatrics, Kitasato University School of Medicine
Shuichi ITO	Yokohama City University
Yoshitsugu KAKU	Department of Nephrology, Fukuoka Children's Hospital
Kenichiro MIURA	Department of Pediatric Nephrology, Tokyo Women's Medical University
Koichi NAKANISHI	Department of Child Health and Welfare (Pediatrics) Graduate School of Medicine, University of the Ryukyus
Kandai NOZU	Department of Pediatrics, Kobe University Graduate School of Medicine
Yuko SHIMA	Pediatrics, Wakayama Medical University
Ryugo HIRAMOTO (Liaison)	Cantabile Pediatric Clinic/Matsudo City General Hospital Children's Medical Centre
Shori TAKAHASHI (ex-liaison)	Assistant Hospital Director, Nihon University Hospital and Nihon University Itabashi Hospital



## General Information

### MEETING DATE AND VENUES

The 22<sup>nd</sup> Korea-China-Japan Pediatric Nephrology Seminar 2026

Date: April 25(Sat), 2026

Venue: Jeju Shinhwa World Hotel & Resort, Jeju, Korea

▶ Landing Convention Centre LGF, Landing Ballroom C



### ACCOMMODATION

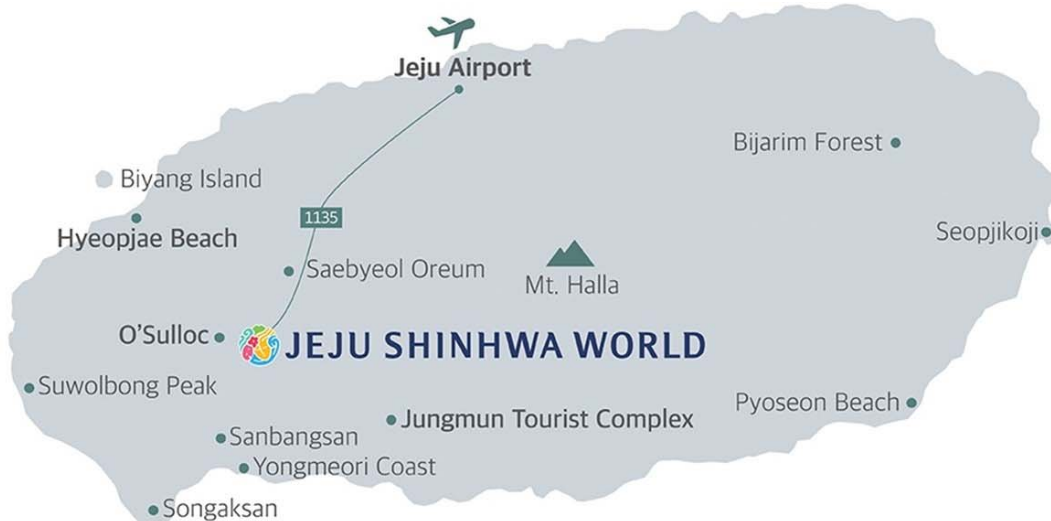The Korean Society of Pediatric Nephrology has assigned the 'Jeju Shinhwa World Hotel & Resort.'

Jeju Shinhwa World Hotel & Resort (Landing Convention Centre LGF, Landing Ballroom C)

Address: 38, Sinhwayeoksa-ro 304beon-gil, Andeok-myeon, Seogwipo-si, Jeju-do, Republic of Korea

Contact Information: General Inquiry (Resort & Attraction)

Tel 82-64-908-8888, E-mail [guestservices@shinhwaworld.com](mailto:guestservices@shinhwaworld.com)



### ORGANIZING COMMITTEE MEETING

Date: Friday 24, April, 18:00 (6:00 PM)

Venue: Jeju Shinhwa World Hotel & Resort, Jeju, Korea

▶ Landing Convention Centre GF, Saebyeol(새별) Room

### CLOSING DINNER

Date: Saturday 25 April, 18:00 (6:00 PM)

Venue: Hwasan (Jeju Shinhwa World)

### CONTINUOUS PROFESSIONAL DEVELOPMENT GUIDELINES

- Total 4 CPD lectures, 2 from hosting country, 1 from each participating country
- Official language: English
- Presentation 25 min, Q&A 5 min, total 30 min

### ORAL PRESENTATION GUIDELINES

- Total 9 Oral Presentation
- Official language: English
- Presentation 20 min, Q&A 5 min, total 25 min

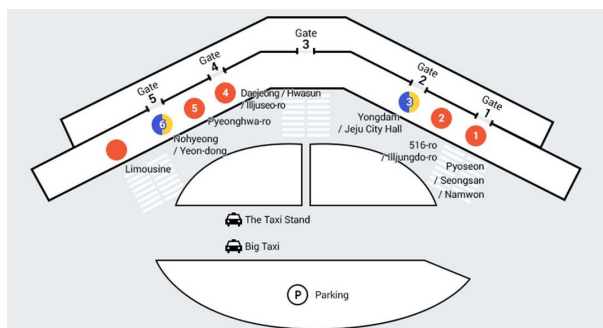
### POSTER ORAL PRESENTATION GUIDELINES

- Total 33 Poster Oral Presentation
  - All Offline Presentation
- Official language: English
- 4 minutes for each presentation, 3 minutes for discussion.
- Presentation Location: Lobby of the seminar venue

### TRANSPORTATION

#### By taxi

crossing the crosswalk in front of Gate 3 on the airport's first floor. The usual time of the trip is approximately 40 minutes, though this may differ based on traffic conditions.





### **By rent-a-car**

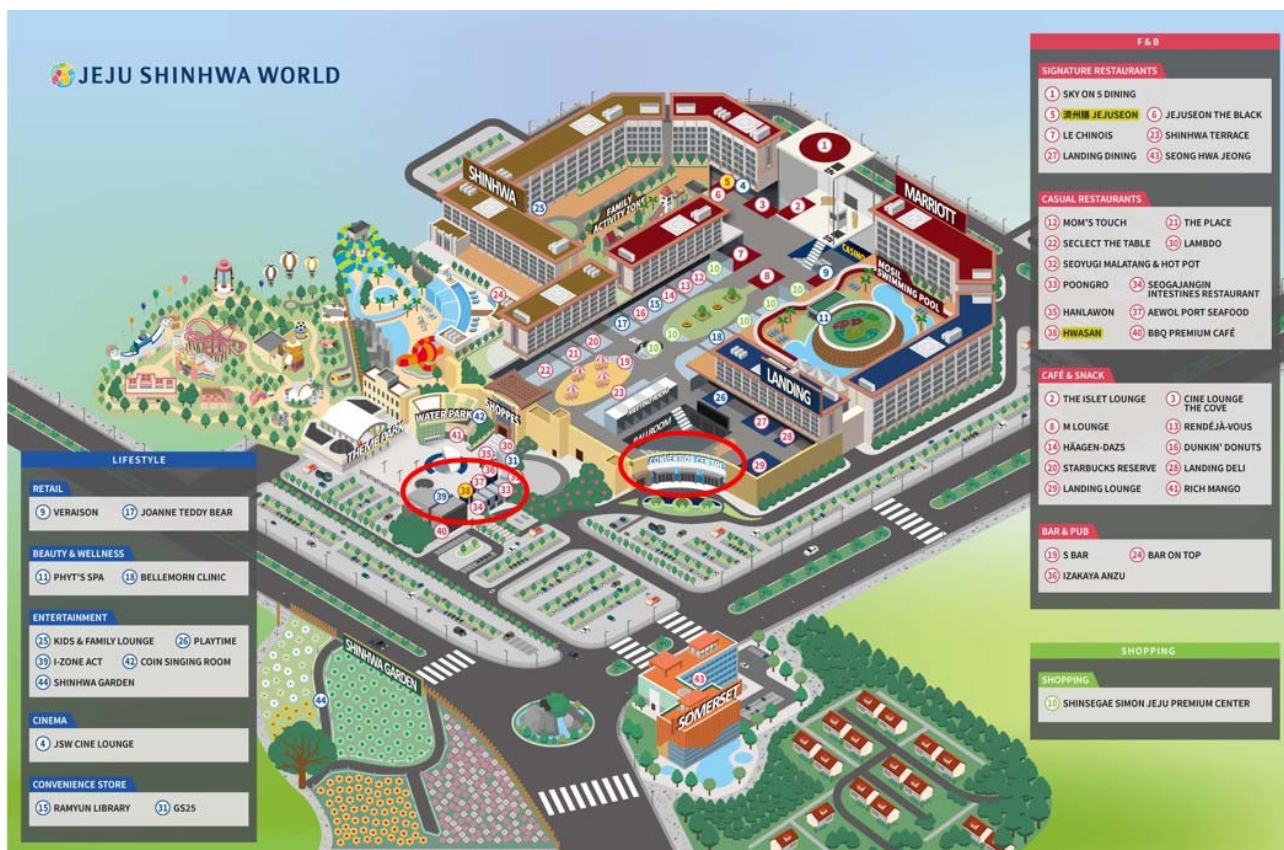After arriving in Jeju, you can pick up your rental car through a pre-booked rental car company. The average duration is approximately 40 minutes and may fluctuate based on the traffic conditions. It is recommended that, upon arrival at the resort, it is more convenient to get off the passenger and luggage in the lobby before moving to parking lot.

※ You will obtain more accurate information if you search for the hotel name you reserved on the navigation.  
(Landing, Shinhwa, Marriott, Somerset)

**By Public Bus:** Please refer to the homepage.

▶ <https://kspn.org/register/2026/venue/sub02.html>

## Guide Map



### Conference Hall

- ▶ Landing Convention Centre LGF, Landing Ballroom C

### Organizing Committee Meeting

Date: Friday 24, April, 18:00 (6:00 PM)

Venue: Jeju Shinhwa World Hotel & Resort, Jeju, Korea

- ▶ Landing Convention Centre GF, Saebyeol(새별) Room

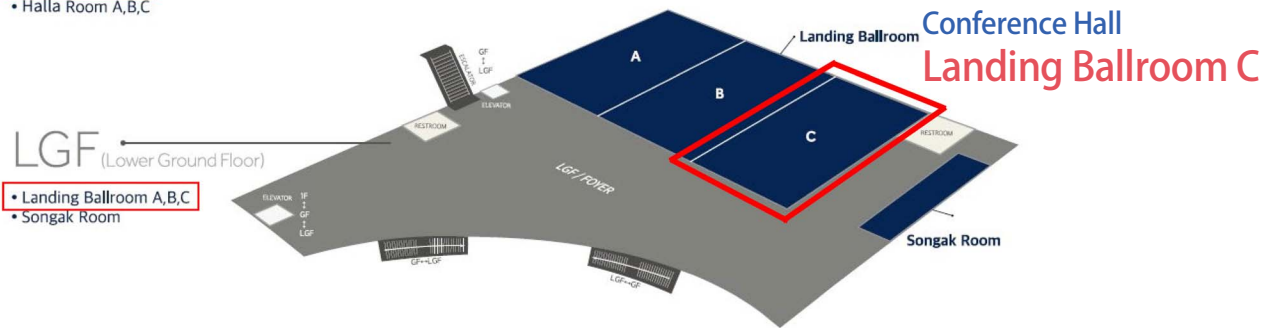
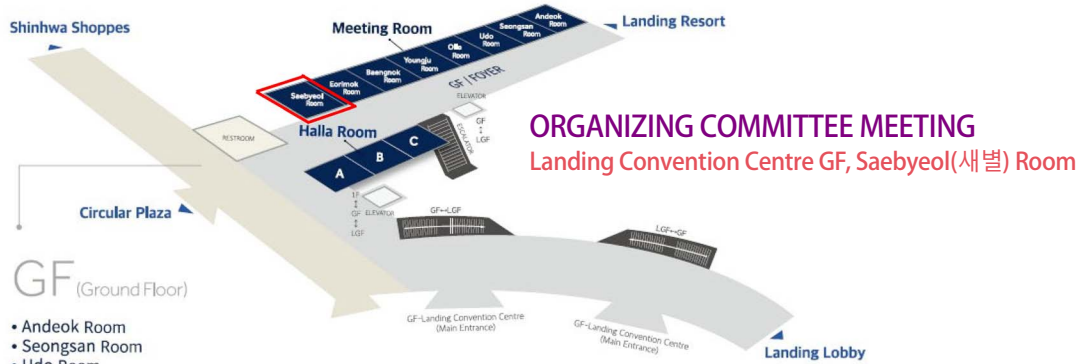### No. 38 : Closing Dinner

Date: Saturday 25 April, 18:00 (6:00 PM)

Venue: Hwasan (Jeju Shinhwa World)

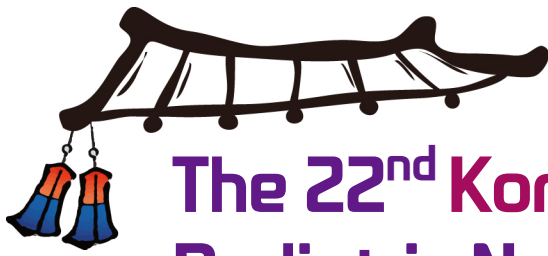

# Floor Guide





# PROGRAM



# The 22<sup>nd</sup> Korea-China-Japan Pediatric Nephrology Seminar 2026

Date: April 25(Sat), 2026

Venue: Jeju Shinhwa World Hotel & Resort, Jeju, Korea

▶ Landing Convention Centre LGF, Landing Ballroom C

08:30-08:55 Registration

08:55-09:00 Opening Remark Joo Hoon Lee (President of the Korean Society of Pediatric Nephrology)

**09:00-09:25 Oral presentation 1** Chairperson: Xuhui Zhong (Peking University First Hospital, China)

09:00-09:20 Clinical utility of targeted genome sequencing in previously undiagnosed cases of Alport syndrome  
Asahi Yamamoto (Kobe University Graduate School of Medicine, Japan)

09:20-09:25 Q&A

**09:25-09:50 Oral presentation 2**  
Chairperson: Toru UCHIMURA (Yokohama City University Medical Center, Japan)

09:25-09:45 When Chronic Tubulointerstitial Nephropathy Is Not Inflammatory: Reanalysis of Genome Sequencing Identifies ANKS6 Variants in Early-Onset ESKD  
Na Ye Choi (Seoul National University Children's Hospital, Korea)

09:45-09:50 Q&A

**09:50-10:15 Oral presentation 3**  
Chairperson: Min Hyun Cho (Kyungpook National University Hospital, Korea)

09:50-10:10 Is this a case of IgA nephropathy, Alport syndrome or Frasier syndrome?  
Fang Yang<sup>1</sup>, Shuling Yue<sup>2</sup>  
(<sup>1</sup>The First Affiliated Hospital of Jinan University, <sup>2</sup>Guangzhou Kingmed clinical Laboratory, China)

10:10-10:15 Q&A

**10:15-10:40 Oral presentation 4** Chairperson: Jung Won Lee (Ewha Womans University Medical Center, Korea)

10:15-10:35 Utility of anti-nephrin autoantibody-to-IgG ratio in autoimmune podocytopathies  
Yoko Shirai (Tokyo Women's Medical University, Japan)

10:35-10:40 Q&A

10:40-10:55 Coffe Break

10:55-11:20 Oral presentation 5

Chairperson: Yulin Kang (Shanghai Children's Hospital, Shanghai Jiao Tong University School of Medicine, China)

10:55-11:15 Lupus Nephritis as a Manifestation of TNFAIP3-Related A20 Haploinsufficiency

**Hannah Yoon** (Seoul National University Children's Hospital, Korea)

11:15-11:20 Q&A

11:20-11:45 Oral presentation 6 Chairperson: Chikako TERANO (Kitasato University School of Medicine, Japan)

11:20-11:40 Incident IgA Nephropathy shortly followed with seroconversion of positive anti-GBM antibodies and rapid progression of glomerulonephritis in a Chinese boy: same disease or overlaped process?

**Xu Zhang** (Tongji Hospital, Tongji Medical College, Huazhong University of Science & Technology, China)

11:40-11:45 Q&A

11:45-12:10 Oral presentation 7 Chairperson: Hyung Eun Yim (Korea University Ansan Hospital, Korea)

11:45-12:05 High-sensitivity anti-nephrin autoantibody assay predicts steroid resistance and glomerulonephritis in childhood idiopathic nephrotic syndrome

**Tomoko Horinouchi** (Kobe University Graduate School of Medicine, Japan)

12:05-12:10 Q&A

12:10-13:00 Lunch

13:00-13:25 Oral presentation 8

Chairperson: Liangzhong Sun (Nanfang Hospital, Southern Medical University, China)

13:00-13:20 Two Infants with TSC and Early Renal Cysts: Implications for Genomic Evaluation

**Eujin Park** (Korea University College of Medicine, Korea)

13:20-13:25 Q&A

13:25-13:50 Oral presentation 9

Chairperson: Shunsuke SHINOZUKA (Matsudo City General Hospital Children's Medical Centre, Japan)

13:25-13:45 Abernethy malformation type Ib combined with membranoproliferative glomerulonephritis: a case received liver transplantation

**Anna Shen** (Shanghai Children's Hospital, Shanghai Jiao Tong University School of Medicine, China)

13:45-13:50 Q&A



13:50-14:50 Poster presentation with Chair

Chairperson: Nao UCHIDA (Tohoku University Hospital, Japan)  
Ji Hyeon Kim (Seoul National University Bundang Hospital, Korea)  
Yo Han Ahn (Seoul National University Children's Hospital, Korea)  
Jae Il Shin (Severance Children's Hospital, Yonsei University College of Medicine, Korea)

14:50-15:10 Coffee Break

15:10-15:40 Continuous Professional Development 1

Chairperson: Heeyeon Cho (Samsung Medical Center, Sungkyunkwan University, Korea)

15:10-15:35 Genetic causes of steroid-resistant nephrotic syndrome (SRNS)

**Fang Wang** (Department of Pediatric Nephrology, Peking University First Hospital, China)

15:35-15:40 Q&A

15:40-16:10 Continuous Professional Development 2

Chairperson: Riku HAMADA (Tokyo Metropolitan Children's Medical Center, Japan)

15:40-16:05 KEYNOTE: a nationwide prospective cohort of pediatric nephrotic syndrome in Korea

**Eun Mi Yang** (Department of Pediatrics, Chonnam National University School, Korea)

16:05-16:10 Q&A

16:10-16:40 Continuous Professional Development 3

Chairperson: Jianhua Zhou (Tongji Hospital, Tongji Medical College, Huazhong University of Science and Technology, China)

16:10-16:35 National guideline in pediatric nephrotic syndrome in Korea

**Hyunkyung Lee** (Department of Pediatrics, Chung-Ang University, Korea)

16:35-16:40 Q&A

16:40-17:10 Continuous Professional Development 4

Chairperson: Kyoung Hee Han (Jeju National University Hospital, Korea)

16:40-17:05 How to delay and how to treat chronic kidney disease (CKD)

**Yusuke Okuda** (Department of Pediatrics, Kitasato University School of Medicine, Japan)

17:05-17:10 Q&A

## Contents

### Continuous Professional Development

- CP01** Genetic causes of steroid-resistant nephrotic syndrome (SRNS) ..... 3  
**Fang Wang** (Department of Pediatric Nephrology, Peking University First Hospital, China)
- CP02** KEYNOTE: a nationwide prospective cohort of pediatric nephrotic syndrome in Korea ..... 4  
**Eun Mi Yang** (Department of Pediatrics, Chonnam National University School, Korea)
- CP03** National guideline in pediatric nephrotic syndrome in Korea ..... 5  
**Hyunkyung Lee** (Department of Pediatrics, Chung-Ang University, Korea)
- CP04** How to delay and how to treat chronic kidney disease (CKD) ..... 21  
**Yusuke Okuda** (Department of Pediatrics, Kitasato University School of Medicine, Japan)

### Oral Presentation

- O-1** Clinical utility of targeted genome sequencing in previously undiagnosed cases of Alport syndrome ..... 25  
**Asahi Yamamoto<sup>1,2</sup>**, **China Nagano<sup>1</sup>**, **Shuhei Aoyama<sup>1</sup>**, **Yuka Kimura<sup>1</sup>**, **Yuta Inoki<sup>1</sup>**, **Nana Sakakibara<sup>1</sup>**, **Tomoko Horinouchi<sup>1</sup>**, **Tomohiko Yamamura<sup>1</sup>**, **Shingo Ishimori<sup>1</sup>**, **Takayuki Okamoto<sup>2</sup>**, **Kandai Nozu<sup>1</sup>**  
 (<sup>1</sup>Department of Pediatrics, Kobe University Graduate School of Medicine, <sup>2</sup>Department of Pediatrics, Hokkaido University Graduate School of Medicine)
- O-2** When Chronic Tubulointerstitial Nephropathy Is Not Inflammatory: Reanalysis of Genome Sequencing Identifies ANKS6 Variants in Early-Onset ESKD ..... 27  
**Naye Choi<sup>1,2</sup>**, **Hyuna Lee<sup>3</sup>**, **Ji Hyun Kim<sup>2,4</sup>**, **Jung Sue Kim<sup>5</sup>**, **Hae Il Cheong<sup>6</sup>**, **Hee Gyung Kang<sup>1,2</sup>**, **Yo Han Ahn<sup>1,2</sup>** (<sup>1</sup>Department of Pediatrics, Seoul National University Children's Hospital, Seoul, Korea, <sup>2</sup>Department of Pediatrics, Seoul National University College of Medicine, Seoul, Korea, <sup>3</sup>Department of Pediatrics, Ajou University Hospital, Suwon, Korea, <sup>4</sup>Department of Pediatric, Seoul National University Bundang Hospital, Seongnam-si, Korea, <sup>5</sup>Department of Pediatrics, Cheongju St. Mary's Hospital, Cheongju, Korea, <sup>6</sup>Department of Pediatrics, Seoul Red Cross Hospital, Seoul, Korea)
- O-3** Is this a case of IgA nephropathy, Alport syndrome or Frasier syndrome? ..... 29  
**Fang Yang<sup>1</sup>**, **Shuting Peng<sup>1</sup>**, **Zhengye Tian<sup>1</sup>**, **Ding Liu<sup>1</sup>**, **Jieying Feng<sup>1</sup>**, **Shuling Yue<sup>2</sup>**  
 (<sup>1</sup>Department of Pediatric nephrology, the First Affiliated Hospital of Jinan University, Guangzhou, China, <sup>2</sup>Department of Pathology, Guangzhou Kingmed clinical Laboratory, China)



- O-4** Utility of anti-nephrin autoantibody-to-IgG ratio in autoimmune podocytopathies ..... 31  
**Yoko Shirai<sup>1</sup>, Kenichiro Miura<sup>1</sup>, Keiichi Takizawa<sup>2</sup>, Yutaka Harita<sup>2</sup>, Etsuko Tanaka<sup>3</sup>, Kiyohiko Hotta<sup>4</sup>, Saori Nishio<sup>5</sup>, Motoshi Hattori<sup>1</sup>** (<sup>1</sup>Department of Pediatric Nephrology, Tokyo Women's Medical University, Tokyo, Japan, <sup>2</sup>Department of Pediatrics, the University of Tokyo, Tokyo, Japan, <sup>3</sup>Department of Pediatrics, Faculty of Medicine, University of Miyazaki, <sup>4</sup>Department of Renal and Genitourinary Surgery, Faculty of Medicine, Hokkaido University, <sup>5</sup>Department of Hemodialysis and Apheresis, Hokkaido University Hospital)
- O-5** Lupus Nephritis as a Manifestation of TNFAIP3-Related A20 Haploinsufficiency ..... 33  
**Hannah Yoon, Na Ye Choi, Yo Han Ahn, Hee Kyung Kang, Seong Heon Kim** (Department of Pediatrics, Seoul National University Children's Hospital, Seoul, Korea)
- O-6** Incident IgA Nephropathy shortly followed with seroconversion of positive anti-GBM antibodies and rapid progression of glomerulonephritis in a Chinese boy: same disease or overlapped process? ..... 35  
**Xu Zhang, Fengjie Yang, Shiyi Wu, Yu Zhang, Jianhua Zhou** (Department of Pediatrics, Tongji Hospital, Tongji Medical College, Huazhong University of Science & Technology, Wuhan, 430030, Hubei Province, China)
- O-7** High-sensitivity anti-nephrin autoantibody assay predicts steroid resistance and glomerulonephritis in childhood idiopathic nephrotic syndrome ..... 37  
**Tomoko Horinouchi<sup>1</sup>, Masaya Muto<sup>2</sup>, Yuta Inoki<sup>1</sup>, Natsumi Yamamura<sup>3</sup>, Koichi Kamei<sup>4</sup>, Rika Fujimaru<sup>5</sup>, Miwa Goto<sup>6</sup>, Hiroki Miyano<sup>7</sup>, Rie Kuroki<sup>8</sup>, Tomoo Kise<sup>9</sup>, Hideki Ban<sup>10</sup>, Kazuki Tanaka<sup>11</sup>, Riku Hamada<sup>12</sup>, Yumiko Sakai<sup>2</sup>, Amane Harada<sup>2</sup>, China Nagano<sup>1</sup>, Kandai Nozu<sup>1</sup>, Kazumoto Iijima<sup>1</sup>** (<sup>1</sup>Kobe University, <sup>2</sup>Sysmex Corporation, <sup>3</sup>Osaka Women's and Children's Hospital, <sup>4</sup>National Center for Child Health and Development, <sup>5</sup>Osaka City General Hospital, <sup>6</sup>University of Yamanashi, <sup>7</sup>Juntendo University Nerima Hospital, <sup>8</sup>Japanese Red Cross Fukuoka Hospital, <sup>9</sup>Okinawa Prefectural Nanbu Medical Center & Children's Medical Center, <sup>10</sup>Japanese Red Cross Kumamoto Hospital, <sup>11</sup>Aichi Children's Health and Medical Center, <sup>12</sup>Tokyo Metropolitan Children's Medical Center)
- O-8** Two Infants with TSC and Early Renal Cysts: Implications for Genomic Evaluation ..... 39  
**Hyun Seo Kim, Jung Hye Byeon, Juyoung Lee, Dong Hwa Yang, Eujin Park** (Department of Pediatrics, Korea University College of Medicine)
- O-9** Abernethy malformation type Ib combined with membranoproliferative glomerulonephritis: a case received liver transplantation ..... 40  
**Anna Shen<sup>1</sup>, Weihua Zheng<sup>1</sup>, Wenyan Huang<sup>1</sup>, Yun Cui<sup>2</sup>, Yucai Zhang<sup>2</sup>, Yulin Kang<sup>1</sup>** (<sup>1</sup>Department of Nephrology and Rheumatology, Shanghai Children's Hospital, Shanghai Jiao Tong University School of Medicine, Shanghai, China, <sup>2</sup>Department of Critical Care Medicine, Shanghai Children's Hospital, Shanghai Jiao Tong University School of Medicine, Shanghai, China)

Poster Presentation

- P1-1** An Unusual Cause of Acute Kidney Injury with Severe Lactic Acidosis: Kidney Infiltration by B-Cell Lymphoblastic Lymphoma in a Pediatric Patient ..... 45  
**Soo Kyung Lee<sup>1</sup>, Hyoung Soo Choi<sup>2,3</sup>, Ji Hyun Kim<sup>2,3</sup>** (<sup>1</sup>Department of Pediatrics, Seoul National University Children's Hospital, Seoul, South Korea, <sup>2</sup>Department of Pediatrics, Seoul National University Bundang Hospital, Seongnam, South Korea, <sup>3</sup>Department of Pediatrics, Seoul National University College of Medicine, Seoul, South Korea)
- P1-2** A Case of Distal Renal Tubular Acidosis Diagnosed from Poor Weight Gain in a Female Infant ..... 47  
**Koki Ota, Yuji Moto, Junichiro Araki, Shingo Niimi, Keishirou Houjou, Yuusuke Hiyoshi, Yasuhiro Yoshida, Satoko Kurata, Seiji Tanaka** (Department of Pediatrics and Child Health, Kurume University)
- P1-3** Case Report: Infantile Nephropathic Cystinosis ..... 48  
**Wei Bai, Xuhui Zhong** (Peking University First Hospital)
- P1-4** Renal Manifestations of Baraitser-Winter Cerebrofrontofacial Syndrome: A Case Report ..... 50  
**Yeonhee Lee** (Department of Pediatrics, Seoul St. Mary's Hospital, College of Medicine, The Catholic University of Korea, Seoul, South Korea)
- P1-5** TSC2-PKD1 Contiguous Gene Syndrome With Rapid Cystic Growth in Early Infancy ..... 52  
**Hiromi Mori<sup>2</sup>, Nao Uchida<sup>1</sup>, Yurika Uematsu<sup>1</sup>, Miyu Sai<sup>1</sup>, Takuto Miura<sup>1,3</sup>, Toshinari Takahashi<sup>1,4</sup>, Tetsushi Inagaki<sup>2</sup>, Atsuo Kikuchi<sup>1</sup>** (<sup>1</sup>Department of Pediatrics, Tohoku University Hospital, <sup>2</sup>Department of Nephrology, Miyagi Children's Hospital, <sup>3</sup>Department of Pediatrics, Tome City Hospital, <sup>4</sup>Tsukidate Children's Clinic)
- P1-6** Deep Intronic IFT172 Variants Causing Cryptic Exon Activation Identified by Whole Genome Sequencing in Nephropathy ..... 54  
**Shuhei Aoyama<sup>1</sup>, China Nagano<sup>1</sup>, Asahi Yamamoto<sup>1,2</sup>, Yuka Kimura<sup>1</sup>, Yuta Inoki<sup>1</sup>, Nana Sakakibara<sup>1</sup>, Tomoko Horinouchi<sup>1</sup>, Tomohiko Yamamura<sup>1</sup>, Shingo Ishimori<sup>1</sup>, Naoya Morisada<sup>3</sup>, Kandai Nozu<sup>1</sup>** (<sup>1</sup>Department of Pediatrics, Kobe University Graduate School of Medicine, Kobe, Japan, <sup>2</sup>Department of Pediatrics, Hokkaido University Graduate School of Medicine, Sapporo, Japan, <sup>3</sup>Department of Clinical Genetics, Hyogo Prefectural Children's Hospital, Kobe, Japan)
- P1-7** Genetic Diagnosis of Pediatric Autosomal Dominant Polycystic Kidney Disease: A Retrospective Review at Our Center ..... 55  
**Wataru Shimabukuro<sup>1</sup>, Tomoki, Akamine<sup>1</sup>, Shogo Nakada<sup>1</sup>, Kazuya Hamada<sup>1</sup>, Noriko Kinjo<sup>1</sup>, Yu Tanaka<sup>2</sup>, Naoya Morisada<sup>3,4</sup>, Kandai Nozu<sup>4</sup>, Koichi Nakanishi<sup>1</sup>** (<sup>1</sup>Department of Child Health and Welfare (Pediatrics), Graduate School of Medicine, University of the Ryukyus, Nishihara, Okinawa, Japan, <sup>2</sup>Department of Nephrology, Hyogo Prefectural Kobe Children's Hospital, Kobe, Hyogo, Japan, <sup>3</sup>Department of Clinical Genetics, Hyogo Prefectural Kobe Children's Hospital, Kobe, Hyogo, Japan, <sup>4</sup>Department of Pediatrics, Kobe University Graduate School of Medicine, Kobe, Hyogo, Japan)
- P1-8** Hepatorenal Ciliopathy Mimicking Autosomal Recessive Polycystic Kidney Disease in Childhood .. 56  
**Hee Sun Baek, Min Ji Park, Min Hyun Cho** (Department of Pediatrics, Kyungpook National University, School of Medicine, Daegu, Republic of Korea)



- P2-1** Severe Early-Onset Cystic Kidney Disease Associated with a De Novo Heterozygous NEK8 Variant: An ARPKD-Mimicking Phenotype ..... 58  
**Hyuna Lee<sup>1</sup>, Jeesu Min<sup>2</sup>, Naye Choi<sup>3,4</sup>, Jung Sue Kim<sup>5</sup>, Ji Hyun Kim<sup>4,6</sup>, Hee Gyung Kang<sup>3,4</sup>, Yo Han Ahn<sup>3,4</sup>**  
(<sup>1</sup>Department of Pediatrics, Ajou University Hospital, Suwon, Korea, <sup>2</sup>Department of Pediatric, Chungnam National University Sejong Hospital, Sejong, Korea, <sup>3</sup>Department of Pediatric, Seoul National University Children's Hospital, Seoul, Korea, <sup>4</sup>Department of Pediatric, Seoul National University College of Medicine, Seoul, Korea, <sup>5</sup>Department of Pediatric, Cheongju St.Mary's Hospital, Cheongju, Korea, <sup>6</sup>Department of Pediatric, Seoul National University Bundang Hospital, Seongnam-si, Korea)
- P2-2** Genotype–phenotype analysis of renal tubular dysgenesis caused by angiotensinogen variants ... 60  
**Yuka Kimura<sup>1</sup>, China Nagano<sup>1</sup>, Koichi Kamei<sup>2</sup>, Kentaro Nishi<sup>2</sup>, Kano Yuji<sup>3</sup>, Hiroshi Suzumura<sup>3</sup>, Asahi Yamamoto<sup>1</sup>, Shuhei Aoyama<sup>1</sup>, Yuta Inoki<sup>1</sup>, Nana Sakakibara<sup>1</sup>, Tomoko Horinouchi<sup>1</sup>, Tomohiko Yamamura<sup>1</sup>, Shingo Ishimori<sup>1</sup>, Naoya Morisada<sup>4</sup>, Kandai Nozu<sup>1</sup>** (<sup>1</sup>Department of Pediatrics, Kobe University Graduate School of Medicine, Kobe, Japan, <sup>2</sup>Division of Nephrology and Rheumatology, National Center for Child Health and Development, Tokyo, Japan, <sup>3</sup>Department of Pediatrics, Dokkyo Medical University, Tochigi, Japan, <sup>4</sup>Department of Clinical Genetics, Hyogo Prefectural Kobe Children's Hospital, Kobe, Japan)
- P2-3** RNF213-Associated Vasculopathy with Renal and Pulmonary Artery Stenosis in a Child with Moyamoya Disease ..... 62  
**Jun Sada<sup>1</sup>, Chikako Terano<sup>1,2</sup>, Mayuko Terasawa<sup>1</sup>, Ryo Masaoka<sup>1</sup>, Masatoshi Yoshikane<sup>1</sup>, Hisaki Kawamukai<sup>1</sup>, Kazuki Tanaka<sup>1</sup>, Naoya Fujita<sup>1</sup>** (<sup>1</sup>Department of Nephrology, Aichi Children's Health and Medical Center, Aichi, Japan, <sup>2</sup>Department of Pediatrics, Kitasato University School of Medicine, Kanagawa, Japan)
- P2-4** Genetic Variants in Pediatric Renovascular Hypertension: A Single-Center Study ..... 64  
**Jeong Yeon Kim, Heeyeon Cho** (Department of Pediatrics, Samsung Medical Center, Sungkyunkwan University School of Medicine, Seoul, South Korea)
- P2-5** Clinical features and genetic variations in 5 children with Schimke immunoskeletal dysplasia ..... 66  
**Qian Li, Shuzhen Sun, Suwen Liu, Lichun Yu, Jing Wang, Zhenle Yang, Cong Wang, Xiaoyuan Wang**  
(Department of Pediatric Nephrology and Rheumatism and Immunology, Shandong Provincial Hospital Affiliated to Shandong First Medical University, Jinan 250021, P. R. China)
- P2-6** An Infant girl with Frasier syndrome detected through the kindergarten urinalysis screening test .. 67  
**Masayuki Ishihara<sup>1</sup>, Yoshiki Nagao<sup>1</sup>, Haruki Mishima<sup>1</sup>, Yuta Inoki<sup>2</sup>, Nana Sakakibara<sup>2</sup>, China Nagano<sup>2</sup>, Kandai Nozu<sup>2</sup>, Mariko Taniguchi-Ikeda<sup>1</sup>** (<sup>1</sup>Department of Pediatrics, Kochi Medical School, Kochi University, <sup>2</sup>Department of Pediatrics, Kobe University Graduate School of Medicine)
- P2-7** A Case of Frasier Syndrome with Hereditary FSGS Responsive to Cyclosporine ..... 68  
**Shingo Niimi<sup>1</sup>, Yusuke Hiyoshi<sup>1</sup>, Satoko Kurata<sup>1</sup>, Kandai Nozu<sup>2</sup>, Seiji Tanaka<sup>1</sup>** (<sup>1</sup>Department of Pediatrics, Kurume University School of Medicine, Japan, <sup>2</sup>Department of Pediatrics, Kobe University Graduate School of Medicine, Japan)

- P2-8** Infantile-onset X-linked Alport syndrome with predominant tubulointerstitial fibrosis and impaired tubular organization in patient-derived kidney organoids ..... 69  
**Panpan Shao, Yonghua He, Liru Qiu** (Department of Pediatrics, Tongji Hospital, Tongji Medical College, Huazhong University of Science and Technology, Wuhan, PR China 430030)
- P2-9** A Case of Male Infantile Neuroblastoma Who Developed Refractory Hypertension Due to Excessive Catecholamine after Aparotomy Biopsy ..... 71  
**Ryouta Agune, Seiji Tanaka, Shingo Niimi, Keishirou Houjou, Yuusuke Hiyoshi, Junpei Mukai, Shuichi Ozono, Ryuta Nishikomori** (Department of Pediatrics and Child Health, Kurume University)
- P3-1** Compound Heterozygous RRM2B Mutations Associated with Nephrotic Syndrome and Multiple Systemic Abnormalities in a Pediatric Patient ..... 72  
**Lei Sun, Xin-yu Kuang, Wen-yan Huang, Yu-lin Kang** (Department of Nephrology and Rheumatology, Shanghai Children's Hospital, School of Medicine, Shanghai Jiaotong University, Shanghai, 200062, China)
- P3-2** A rare case of steroid-sensitive nephrotic syndrome (SSNS) with podocytopathy in a child with Alport syndrome ..... 74  
**Keum Hwa Lee<sup>1,2</sup>, Peong Gang Park<sup>1,2</sup>, Minsun Jung<sup>3</sup>, Ye Eun Ko<sup>4</sup>, Jae Il Shin<sup>1,2</sup>, Ji Hong Kim<sup>1,5</sup>**  
 (<sup>1</sup>Department of Pediatrics, Yonsei University College of Medicine, Seoul, Republic of Korea, <sup>2</sup>Division of Pediatric Nephrology, Severance Children's Hospital, Yonsei University College of Medicine, Seoul, Republic of Korea, <sup>3</sup>Department of Pathology, Yonsei University College of Medicine, Seoul, Republic of Korea, <sup>4</sup>Department of Internal Medicine, Yonsei University College of Medicine, Seoul, Republic of Korea, <sup>5</sup>Department of Pediatrics, Gangnam Severance Hospital, Seoul, Republic of Korea)
- P3-3** Delayed diagnosis of COQ8B nephropathy following an initial diagnosis of focal segmental glomerulosclerosis ..... 76  
**Sakiko Oboshi<sup>1</sup>, Yuko Shima<sup>1</sup>, Hironobu Mukaiyama<sup>1</sup>, Yu Tanaka<sup>1</sup>, Tomoko Horinouchi<sup>2</sup>, Kandai Nozu<sup>2</sup>, Daisuke Tokuhara<sup>1</sup>, Norishige Yoshikawa<sup>3</sup>** (<sup>1</sup>Pediatrics, Wakayama Medical University, <sup>2</sup>Department of Pediatrics, Kobe University Graduate School of Medicine, <sup>3</sup>Clinical Reserch Center, Takatsuki General Hospital)
- P3-4** Revisiting Age-Related Declines in Urinary Protein Excretion Using Fractional Excretion of Total Protein ..... 77  
**Shoichi Shimizu<sup>1</sup>, Shori Takahashi<sup>2</sup>, Kimitaka Nakazaki<sup>1</sup>, Tamaki Morohashi<sup>1</sup>, Ichiro Morioka<sup>1</sup>**  
 (<sup>1</sup>Department of Pediatrics and Child Health, Nihon University School of Medicine, Tokyo, Japan, <sup>2</sup>Itabashi Chuo Medical Center, Tokyo, Japan)
- P3-5** Secukinumab in the management of generalized pustular psoriasis comorbidity with nephrotic syndrome in a young child with IL36RN variant ..... 79  
**Weina Zhang<sup>1</sup>, Xiaohong Wu<sup>2</sup>, Min Li<sup>1</sup>, Yong Cai<sup>1</sup>, Hongrong Lin<sup>1</sup>, Huamu Chen<sup>1</sup>, Wei Han<sup>1</sup>, Wencheng Li<sup>3</sup>, Liangzhong Sun<sup>1</sup>** (<sup>1</sup>Department of Pediatrics, Nanfang Hospital, Southern Medical University, Guangzhou 510515, China, <sup>2</sup>Department of Pediatrics, People's Hospital Of Shantou, Shantou 515011, China, <sup>3</sup>Department of Pediatric Nephrology, Guangdong Women and Children Hospital, Guangzhou 511442, China)



- P3-6** Rituximab combined with daratumumab in the treatment of a child with multidrug-resistant nephrotic syndrome ..... **80**  
**Ke Xu, Baige Su, Xiaoyu Liu, Xuhui Zhong, Huijie Xiao, Fang Wang** (Department of Pediatrics, Peking University First Hospital, Beijing, China)
- P3-7** Renal-predominant pediatric primary Sjögren's syndrome complicated by EBV-associated immune dysregulation and serositis: a case report ..... **82**  
**Ling Hou, Yue Du** (Department of Pediatrics, Shengjing Hospital of China Medical University, Shenyang, China)
- P3-8** A Complex Case of Recurrent Hematuria, Proteinuria, and Chronic Diarrhea in an Adolescent Male: A Multidisciplinary Challenge ..... **84**  
**MiLan, Wang Hui** (National Center for Children's Health, Beijing Children's Hospital, Capital Medical University, Beijing, China)
- P4-1** A case of C3 glomerulonephritis with normalized C3 levels following initiation of oral levothyroxine therapy for Hashimoto's thyroiditis ..... **87**  
**Yooka Nam<sup>1</sup>, Shunsuke Shinozuka<sup>1</sup>, Bunshiro Akikusa<sup>2</sup>, Ryugo Hiramoto<sup>1,3</sup>** (<sup>1</sup>Department of Pediatrics, Children's Medical Centre, Matsudo City General Hospital, Japan, <sup>2</sup>Department of Pathology, Matsudo City General Hospital, Japan, <sup>3</sup>Cantabile Pediatric Clinic, Japan)
- P4-2** SLE-associated thrombotic microangiopathy with refractory pericardial effusion and cardiac tamponade rescued by pericardial fenestration and rituximab: a case report ..... **89**  
**Fumika Yurugi<sup>1</sup>, Toru Uchimura<sup>2</sup>, Yu Kamigaki<sup>2</sup>, Jotaro Harada<sup>3</sup>, Seira Hattori<sup>1</sup>, Ikuyo Ito<sup>1</sup>, Nishimura Kenichi<sup>1</sup>, Tomo Nozawa<sup>1</sup>, Satoshi Fujii<sup>3</sup>, Junki Koike<sup>4</sup>, Shuichi Ito<sup>1,2</sup>** (<sup>1</sup>Department of Pediatrics, Graduate School of Medicine, Yokohama City University, Japan, <sup>2</sup>Department of Pediatrics, Yokohama City University Medical Center, Japan, <sup>3</sup>Department of Pathology, Graduate School of Medicine, Yokohama City University, Japan, <sup>4</sup>Department of Pathology, Graduate School of Medicine, St. Marianna University School of Medicine, Japan)
- P4-3** Atypical Post-Infectious Glomerulonephritis with Persistent Complement Activation ..... **91**  
**Jiwon Jung, Joo Hoon Lee** (Department of Pediatrics, Asan Medical Center Children's Hospital, University of Ulsan College of Medicine, Seoul, Korea)
- P4-4** Rapidly Progressive Poststreptococcal Glomerulonephritis in a Child: Diagnostic Pitfalls in an Atypical Presentation ..... **93**  
**Tae-Yang Choi, Hyung Eun Yim** (Department of Pediatrics, Korea University Ansan Hospital, Korea University College of Medicine, Seoul, Republic of Korea)
- P4-5** Effective Eculizumab Therapy in Pediatric SP-HUS Following T-Antigen-Negative Plasma Exchange ... **96**  
**Lu Yin, Yue Du** (Department of Pediatric Nephrology, Shengjing Hospital of China Medical University, Shenyang, Liaoning, China)

- P4-6** The Co-existence of BK Virus Nephropathy with Acute Rejection in a Pediatric Renal Allograft Recipient ..... 97  
**Baige Su<sup>1</sup>, Ke Xu<sup>1</sup>, Suxia Wang<sup>2</sup>, Yali Ren<sup>2</sup>, Wei Wang<sup>3</sup>, Fang Wang<sup>1</sup>, Xuhui Zhong<sup>1</sup>** (<sup>1</sup>Department of Pediatric Nephrology, Peking University First Hospital, China, <sup>2</sup>Laboratory of Electron Microscopy, Ultrastructural Pathology Center, Peking University First Hospital, China, <sup>3</sup>Department of Pathology, Peking University First Hospital, China)
- P4-7** Transplant-associated Thrombotic Microangiopathy after hematopoietic stem cell transplantation in children-a case report ..... 99  
**Haiyan Wang<sup>1,2</sup>, Weiping Tan<sup>1</sup>, Bihong Zhang<sup>1</sup>, Ke Huang<sup>1</sup>, Jianpei Fang<sup>1</sup>, Liangzhong Sun<sup>2</sup>** (<sup>1</sup>Sun Yat-sen Memorial Hospital, Sun Yat-sen University, Guangzhou, China, 510120, <sup>2</sup>Nanfang Hospital, Southern Medical University, Guangzhou, China, 510515)
- P4-8** A Case of Kidney Transplantation in a Patient with Central Diabetes Insipidus ..... 101  
**Rika Fujimaru, Takahiro Fujii, Ryota Sakai** (Division of Pediatric Endocrinology, Metabolism and Nephrology, Osaka City General Hospital, Osaka, Japan)





# Continuous Professional Development





## Genetic causes of steroid-resistant nephrotic syndrome

**Fang Wang**

Department of Pediatrics, Children's Medical Center, Rare Diseases Medical Center, Peking University First Hospital

As the most common glomerular disease in children, nephrotic syndrome is diagnosed based on the coexistence of nephrotic-range proteinuria and hypoalbuminemia. Genetic nephrotic syndrome is characterized by multidrug resistance, including steroid resistance, and a high risk of progression to end-stage kidney disease. This condition may manifest as familial or sporadic, syndromic or non-syndromic, with onset ranging from congenital and infantile through childhood and adolescence to adulthood. In initial steroid-resistant nephrotic syndrome, underlying pathogenic genetic variants in approximately 60 associated genes are identified in about 30% of childhood-onset cases and 10%–15% of adult-onset cases. Therefore, early identification of genetic nephrotic syndrome is pivotal for the precision management of steroid-resistant nephrotic syndrome. Notably, the genetic testing results for pediatric steroid-resistant nephrotic syndrome patients vary with different ethnicities. Age at onset, multidrug resistance (including steroid resistance), extrarenal manifestations in the context of nephrotic syndrome, a positive family history of steroid-resistant nephrotic syndrome or parental consanguinity, and histopathological findings of diffuse mesangial glomerulosclerosis on renal biopsy all serve as important clues for the identification of genetic nephrotic syndrome. Obtaining a definitive diagnosis of genetic nephrotic syndrome has wide-ranging clinical implications.



## KEYNOTE: a nationwide prospective cohort of pediatric nephrotic syndrome in Korea

Eun Mi Yang

Department of Pediatrics, Chonnam national university medical school, Korea

Nephrotic syndrome (NS) is the most common glomerular disorder in children; however, large-scale, longitudinal data on its epidemiology and clinical course in Korea remain limited. Although most children respond well to corticosteroid therapy, a substantial proportion experience frequent relapses, steroid dependence, or steroid resistance, all of which may lead to significant morbidity and prolonged exposure to immunosuppressive agents. Using a nationwide multicenter registry, we aimed to characterize the demographic and baseline clinical features of children with newly diagnosed NS and to evaluate their long-term clinical course over nearly four decades. From 1987 to 2024, a total of 2,564 pediatric patients ( $\leq 18$  years) with incident NS were retrospectively enrolled from 21 centers across Korea. Standardized case report forms were used to collect data from diagnosis through long-term follow-up, including age at onset, sex, anthropometric measures, birth history, laboratory findings, histopathologic features, initial treatment regimens, and longitudinal clinical outcomes. The cohort included 1,820 males (71.0%) and 744 females (29.0%), with a median age at diagnosis of 4.8 years (interquartile range, 3.0–8.6 years). Overall, 81.2% of patients had steroid-sensitive nephrotic syndrome, whereas 18.8% had steroid-resistant nephrotic syndrome. Kidney biopsy was performed in 18.4% of patients, and genetic testing in 1.2%. This nationwide longitudinal cohort provides a comprehensive overview of disease presentation and early management in Korean children with NS over four decades. Continued follow-up of this cohort will provide an important foundation for future studies on relapse patterns, long-term kidney outcomes, genetic determinants, treatment response, and individualized management strategies in pediatric NS.

# National guideline in pediatric nephrotic syndrome in Korea

HyunKyung Lee, M.D., Ph.D.

Department of Pediatrics, Chung-Ang University College of Medicine

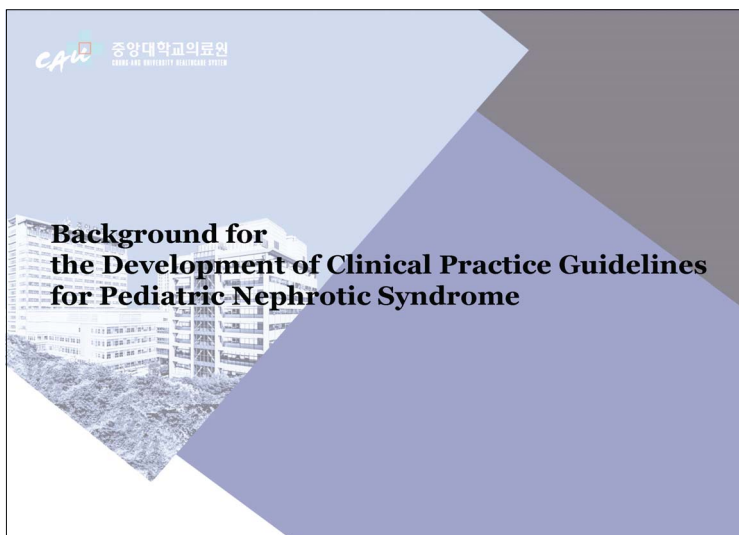
## ► Disclosures

- I have no disclosures relevant to this topic
- Acknowledgment to **Childhood Nephrotic syndrome Guideline Development Group of Korean Society of Pediatric Nephrology**



- |                |              |
|----------------|--------------|
| HyunKyung Lee  | Heeyeon Cho  |
| Min Hyun Cho   | Yeon Hee Lee |
| Jeong Yeon Kim | Joo Hoon Lee |
| Hee Gyung Kang | Eujin Park   |
| Jin-Soon Suh   | Dong Ah Park |

CAU 중앙대학교의료원  
CHUNG-ANG UNIVERSITY MEDICAL CENTER





▶ Development Process & Methodology

- **Quality Assessment & Adoption**  
Evaluated national and international CPGs  
Adopted 3 major guidelines: KDIGO, IPNA, and JSPN
- **Evidence-Based Adaptation**  
Systematic review of prior recommendations and recent research  
Adapted specifically to the Korean healthcare setting
- **GRADE methodology for evidence quality and recommendations**
- **Identification of 5 topics, 6 key questions:**  
relevant to the domestic clinical setting



▶ 5 Key Topics

1. Deflazacort vs Prednisolone
2. Optimal duration of initial steroid therapy
3. Standard vs lower initial steroid dose
4. Mycophenolate mofetil vs Calcineurin inhibitors
5. Cyclophosphamide vs Calcineurin inhibitors



▶ Key Question 1:

- Is **deflazacort** more effective than prednisolone in terms of inducing remission and preventing relapse, with fewer side effects, in children diagnosed with primary nephrotic syndrome?

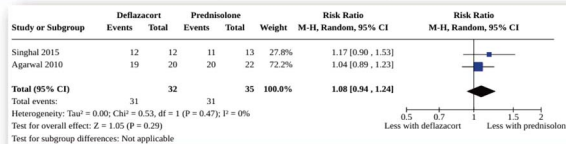




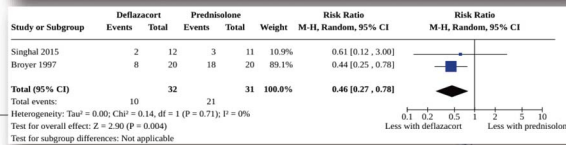
► Clinical Outcomes (Remission/Relapse DFZ vs. PD)

	Broyer (1997, France)	Agarwal (2010, India)	Singhal (2015, India)
Number with complete remission at 6-weeks		No significant difference	More with DFZ, but not statistically significant
Number with relapse by 9 to 12-months	Less with DFZ		Less with DFZ, but not statistically significant

Number with remission

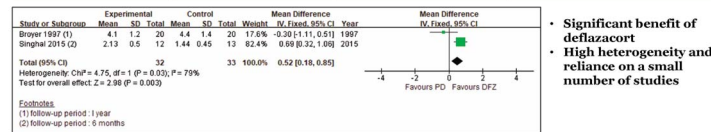


Number with relapse by 9 to 12 months



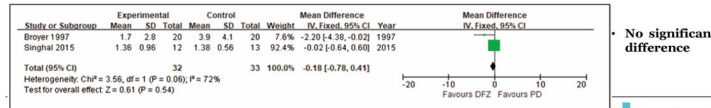
► Side Effects (DFZ vs. PD)

	Broyer (1997, France)	Agarwal (2010, India)	Singhal (2015, India)
Height growth	No significant difference		Greater increase with DFZ



- Significant benefit of deflazacort
- High heterogeneity and reliance on a small number of studies

	Broyer (1997, France)	Agarwal (2010, India)	Singhal (2015, India)
Weight change	Lesser increase with DFZ		No significant difference



- No significant difference

► Side Effects (DFZ vs. PD)

	Broyer (1997, France)	Agarwal (2010, India)	Singhal (2015, India)
Bone mineral density	No significant difference	No significant difference	
Fasting blood glucose levels	No significant difference	No significant difference	No significant difference

- No significant difference in bone density and fasting glucose levels between deflazacort and prednisolone.



### ► Toxic Epidermal Necrolysis (TEN) & Stevens-Johnson Syndrome (SJS)

- No RCT available comparing skin reaction between DFZ and PD
- Only one single-center retrospective study: TEN 3/54 (DFZ) vs 0/40 (PD) in pediatric NS

Kidney Res Clin Pract 31 (2016) 222-225

Lee et al. / Toxic epidermal necrolysis

Kidney Research and Clinical Practice  
journal homepage: <http://www.krcp.knu.ac.kr>  
Contents lists available at ScienceDirect

Case Report  
Toxic epidermal necrolysis associated with deflazacort therapy with nephrotic syndrome  
Eun Chae Lee, Geun A Kim, Ja Wook Koo\*

Department of Pediatrics, Sanggye Park Hospital, Kyung Hee University, College of Medicine, Seoul, Korea

**ABSTRACT**  
Toxic epidermal necrolysis (TEN) is a drug-related fatal disease. Extensive necrosis of the epidermis can lead to serious complications. This report describes two cases of TEN associated with deflazacort (DFZ) in two boys, aged 4 years and 14 years, with nephrotic syndrome (NS). The 14-year-old male (though received DFZ following NS relapse) after 17 days, pruritic papules appeared on the lower extremities. Another case involved a 4-year-old boy receiving DFZ and mitomycin. After a 40-day DFZ treatment period, erythematous papules appeared on the palms and soles. Within 3 days, both Figure 1. Typical pattern of toxic epidermal necrolysis erythema. Both developed widespread skin lesions (>30%) and were admitted to the intensive monitoring, and full-thickness epidermal loss is seen over the entire body after intravenous immunoglobulin-G therapy. Owing to the rapid, fatal course of TEN, clinicians need to be aware of the adverse effects of this drug when treating cases of NS.

© 2016. The Korean Society of Nephrology. Published by Elsevier. This is an open access article under the CC BY-NC-ND license (<http://creativecommons.org/licenses/by-nc-nd/4.0/>)

Figure 1. Typical pattern of toxic epidermal necrolysis erythema. Both developed widespread skin lesions (>30%) and were admitted to the intensive monitoring, and full-thickness epidermal loss is seen over the entire body after intravenous immunoglobulin-G therapy. Owing to the rapid, fatal course of TEN, clinicians need to be aware of the adverse effects of this drug when treating cases of NS.

Figure 2. Remission and crusts on the lips and multiple bullae over the chest.

The extent of epidermal involvement in TEN is more >30%.

A few recently published cases indicate that TEN is induced by several oral (1,2,3). In particular, at one of patients treated with PD did not develop TEN, but the patients treated with DFZ developed TEN. In case 1, the initial treatment with PD and DFZ, no skin lesions developed at that time. However, after readmission high-dose DFZ for more than 2 weeks, TEN developed. Remission was achieved, rashes did not reappear <4

CAU 중앙대학교의료원  
Korea University College of Medicine

### ► Drug of Choice in NS (DFZ vs. PD)

- DFZ: possible benefit in relapse reduction and height growth
- Limitations:
  - few studies
  - high heterogeneity
- Consideration:
  - risk of TEN/SJS
  - higher cost of DFZ

### ► Key Question 1:

- Is deflazacort more effective than prednisolone in terms of inducing remission and preventing relapse, with fewer side effects, in children diagnosed with primary nephrotic syndrome?

#### Recommendation

In pediatric patients with primary nephrotic syndrome, there is no significant difference in drug-related side effects and remission rates between deflazacort and prednisone. Therefore, either deflazacort or prednisone can be selected based on clinical situation and drug costs.  
(Grade of recommendation: Weak, Quality of evidence: Very low)

#### [Clinical considerations]

- While deflazacort and prednisolone have similar remission rates and side effect profiles in pediatric primary nephrotic syndrome, some studies suggest that deflazacort is associated with a lower relapse rate.
- However, due to the higher cost of deflazacort, treatment decisions should consider the values and preferences of both patients and guardians.

▶ Key Question 2:

- Is an **8–12-week course of prednisolone in the initial treatment** of pediatric nephrotic syndrome as clinically safe and effective as longer courses?

CAPD 중앙대학교의료원  
Korea University Medical Center

▶ PD duration at initial treatment

- **Earlier guidelines:**
  - no clear recommendations on tapering during alternate-day dosing
  - resulted in practice variability
- **Recent guidelines, KDIGO 2021** (1B; grade strong, quality of evidence moderate) **and IPNA 2023 guidelines** (grade A, strong recommendation): **recommend no tapering in alternate-day phase**
- **Is tapering truly unnecessary?**
  - concerns: HPA axis suppression, rebound relapse...
- **Review RCTs on PD duration at initial treatment**
  - outcomes: relapse and steroid-related side effects

CAPD 중앙대학교의료원  
Korea University Medical Center

▶ Evidences for PD duration at initial treatment

RCT	Bagga (1999, India)	Teeninga (2013, Netherlands)	Sinha (2015, India)	Yoshikawa (2015, Japan)	Webb (2019, UK) PREDNOS trial	Jamshaid (2022, Pakistan)
<b>Study subjects (number)</b>	NS in children (45)	NS in children (150)	NS in children (181)	NS in children (255)	NS in children (237)	NS in children (150)
<b>Standard vs prolonged</b>	PD 8 vs 16 -weeks	PD 12 vs 24 -weeks	PD 12 vs 24 -weeks	PD 8 vs 24 -weeks	PD 8 vs 16 -weeks	PD 12 vs 16-24 -weeks
<b>Observed variables</b>	Frequency of relapse, frequently relapsing/steroid dependent incidence, steroid side effects	Relapse rate, incidence of frequent relapses, steroid side effects	Relapse frequency, steroid side effects	Time to first relapse, incidence of frequent relapses, and steroid side effects	Time to first relapse, incidence of frequent relapses, and steroid side effects	Relapse rate

CAPD 중앙대학교의료원  
Korea University Medical Center

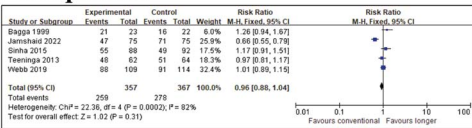


► Outcomes (standard vs. prolonged)

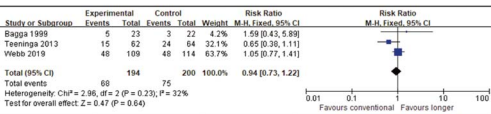
	Bagga (1999, India)	Teeninga (2013, Netherlands)	Sinha (2015, India)	Yoshikawa (2015, Japan)	Webb (2019, UK)	Jamshaid (2022, Pakistan)
<b>Time to first relapse</b>				no significant difference	no significant difference	
<b>Relapse frequency</b>	no significant difference		no significant difference			
<b>Relapse rate</b>		no significant difference				lower relapse rate in standard group
<b>Incidence of SDNS/FRNS</b>	no significant difference	no significant difference		no significant difference	no significant difference	
<b>Steroid side effects</b>	significantly higher in prolonged group	no significant difference	no significant difference	no significant difference	no significant difference	

► Outcomes (standard vs. prolonged)

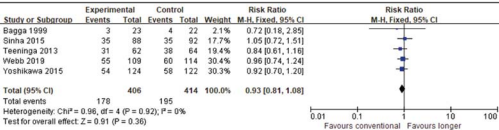
■ Relapse rate



■ Incidence of SDNS



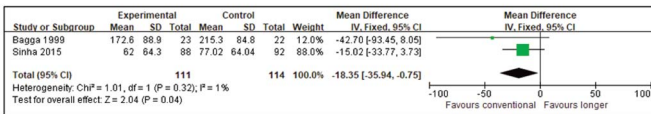
■ Incidence of FRNS



CAU 중앙대학교의료원

► Outcomes (standard vs. prolonged)

■ Cumulative dose of steroid



Control: prolonged treatment (16–24 weeks), Event: standard treatment (8–12 weeks)

CAU 중앙대학교의료원

▶ **Optimal steroid duration in pediatric NS**

- **8 to 12 weeks as initial treatment**
- **No need for additional prolonged therapy**
- **Benefits**
  - **reduce unnecessary drug exposure**
  - **decreases steroid-related side effects**
  - **improves quality of life for patients and caregivers**
  - **lowers healthcare costs**



.....

.....

.....

.....

.....

.....

.....

.....

▶ **Key Question 2:**

- **Is an 8–12-week course of prednisolone in the initial treatment of pediatric nephrotic syndrome as clinically safe and effective as longer courses?**

**Recommendation**

It is recommended to initiate treatment for pediatric nephrotic syndrome with oral prednisolone for 8 to 12 weeks. Prolonged treatment beyond this duration is not advised.

(Grade of recommendation: Strong, Quality of evidence: Low)

**[Clinical considerations]**

- In the initial treatment of pediatric nephrotic syndrome, an 8-week (or 12-week) oral prednisolone regimen involves administering 60 mg/m<sup>2</sup> or 2 mg/kg (maximum 60 mg/day) daily for 4 weeks (or 6 weeks), followed by 40 mg/m<sup>2</sup> or 1.5 mg/kg (maximum 40 mg/day) on alternate days for 4 weeks (or 6 weeks).
- Additional tapering beyond the alternate-day oral prednisolone regimen is not recommended.



.....

.....

.....

.....

.....

.....

.....

.....

▶ **Key Question 3:**

- **(KQ 3-1) Is the administration of an initial dose of prednisolone at 60 mg/m<sup>2</sup>/day or 2 mg/kg/day more effective and safer than lower doses in the initial management of pediatric nephrotic syndrome?**
- **(KQ 3-2) Is the use of 60 mg/m<sup>2</sup>/day or 2 mg/kg/day of prednisolone in the initial treatment of relapsed pediatric nephrotic syndrome safer and more effective than using a lower dose?**



.....

.....

.....

.....

.....

.....

.....

.....



► PD dose for induction: Initial and Relapsed NS

- Prednisolone 60 mg/m<sup>2</sup>/day or 2 mg/kg/day:
  - traditional and effective
  - for induction of remission during initial or relapsed NS
- Effective, but associated with various complications
- Evaluate feasibility of lower initial steroid dose in pediatric NS



► Evidences for induction PD dose in First episode NS (Standard vs. Lower dose)

RCT	Hiraoka (2000, Japan)
Study subjects (number)	NS in children (68)
Standard vs lower dose	PD 60 mg/m <sup>2</sup> /d (6wks) vs. 40 mg/m <sup>2</sup> /d (6wks)
Observed variables	remission rate, cumulative remission rate, sustained remission rate, steroid side effects
Remission rate	no significant difference
Cumulative remission rate	higher in the 60 mg/m <sup>2</sup> /d group
Sustained remission rate	higher in the 60 mg/m <sup>2</sup> /d group
Steroid side effects	higher in the 60 mg/m <sup>2</sup> /d group



► Evidences for induction PD dose in Relapsed NS (Standard vs. Lower dose)

RCT	Seikh (2021, India)	Borovitz (2020, Israel)
Study subjects (number)	Relapsed NS in children (60)	Relapsed NS in children (30)
Standard vs lower dose	PD 2 mg/kg/d vs. 1 mg/kg/d	PD 2 mg/kg/d vs. 1.5 mg/kg/d vs. 1 mg/kg/d
Observed variables	Remission rate, time to remission, time to relapse, cumulative dose of steroid	Remission rate, time to remission, cumulative dose of steroid
Time to remission	No significant difference	No significant difference, but some patient in 1.5 mg and 1 mg group did not achieve remission
Time to relapse	No significant difference	
Cumulative dose of steroid	Significantly higher in 2 mg/kg/d group	Significantly higher in 2 mg/kg/d group



▶ **Optimal induction PD dose in pediatric NS**

- **60 mg/m<sup>2</sup>/day or 2mg/kg/day**
  - standard dose in first episode & relapsed NS
  - clinically effective in maintaining remission
  - higher frequency of steroid-related side effects
- **Insufficient evidence to change current standard treatment**



.....

.....

.....

.....

.....

.....

.....

.....

▶ **Key Question 3:**

**(KQ 3-1) Is the administration of an initial dose of prednisolone at 60 mg/m<sup>2</sup>/day or 2 mg/kg/day more effective and safer than lower doses in the initial management of pediatric nephrotic syndrome?**

**Recommendation**

It is recommended to administer oral prednisolone at a dose of 60 mg/m<sup>2</sup>/day or 2 mg/kg/day (maximum 60 mg/day) for pediatric patients with newly diagnosed nephrotic syndrome.

(Grade of recommendation: Strong, Quality of evidence: Very low)

**(KQ 3-2) Is the use of 60 mg/m<sup>2</sup>/day or 2 mg/kg/ day of prednisolone in the initial treatment of relapsed pediatric nephrotic syndrome safer and more effective than using a lower dose?**

**Recommendation**

It is recommended to administer oral prednisolone at a dose of 60 mg/m<sup>2</sup>/day or 2 mg/kg/day (maximum 60 mg/day) for pediatric patients with relapsing nephrotic syndrome.

(Grade of recommendation: Strong, Quality of evidence: Very low)



.....

.....

.....

.....

.....

.....

.....

.....

▶ **Key Question 4&5: Optimal second-line treatment**

- **Balance between efficacy and safety**
- **Suggested second-line options by international guidelines : oral CYC, levamisole, CNIs, MMF, and rituximab**
- **Comparisons**
  - KQ4: MMF vs. CNIs
  - KQ5: CYC vs. CNIs



.....

.....

.....

.....

.....

.....

.....

.....



▶ Key Question 4:

- Does **mycophenolate mofetil (MMF)** reduce relapse rates and cause fewer side effects compared to calcineurin inhibitors in pediatric nephrotic syndrome patients with steroid dependency or frequent relapses?



.....

.....

.....

.....

.....

.....

.....

.....

.....

.....

▶ Optimal second-line choice in NS (MMF vs. CNIs)

- CNIs
  - effective, but limited by nephrotoxicity
  - concern with long-term use
- MMF
  - fewer drug-related side effects
  - clinically effective option in SDNS or FRNS
- Direct comparison with CNIs
  - evaluate efficacy and safety



.....

.....

.....

.....

.....

.....

.....

.....

.....

.....

▶ Evidences for comparing MMF vs. CNI

	RCT		Single-center prospective			
	Dorresteijn (2008, Netherlands, Belgium)	Gellermann (2013, Germany)	Fujinaga (2013, Japan)	Lim (2015, Korea)	Wang (2016, China)	Jin (2022, China)
<b>Study subjects (number)</b>	FRNS in children (24)	FRNS in children (60)	SDNS (initially with RTX) in children (29)	SDNS in children (35)	FRNS/SDNS in children (72)	FRNS/SDNS in children (56)
<b>Intervention vs Control</b>	MMF (12mo) vs. CsA (12mo)	MMF vs. CsA	MMF vs. CsA	MMF vs. CsA, levamisole	MMF (12mo) vs. Tac (12mo)	MMF vs. CsA, Tac
<b>Observed variables</b>	Relapse rate, drug S/E	Relapse rate, drug S/E	Tx failure rate, remission maintenance, drug S/E	Relapse rate	Relapse rate, drug S/E	Tx response



.....

.....

.....

.....

.....

.....

.....

.....

.....

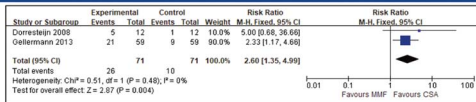
.....

► Evidences for comparing MMF vs. CNI

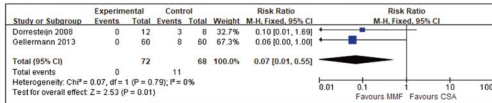
	RCT		Single-center prospective			
	Dorresteijn (2008, Netherlands, Belgium)	Gellermann (2013, Germany)	Fujinaga (2013, Japan)	Lim (2015, Korea)	Wang (2016, China)	Jin (2022, China)
<b>Relapse rate</b>	0.83 vs. 0.08 per year	Higher in MMF group at 1 <sup>st</sup> year, no significant difference at subsequent year	no significant difference	Decreased after MMF Tx than before MMF Tx	no significant difference	All med reaching complete or partial remission
<b>Relapse free frequency</b>		64% vs. 85%			no significant difference	
<b>Remission retention rate</b>			significantly higher in CsA			
<b>Time to relapse</b>					no significant difference	
<b>Drug S/E</b>	CsA: Hirsutism and gingival hyperplasia	CsA: Hirsutism, gingival hyperplasia and leukopenia	CsA: Hirsutism		Both MMF & CsA: leukopenia in some Pt	

► Evidences for comparing MMF vs. CNI

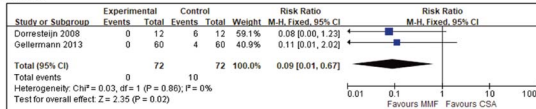
• Relapse rate



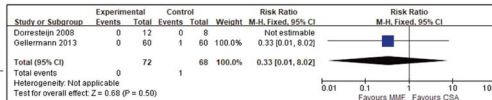
• Hirsutism



• Gingival hyperplasia



• Leukopenia



► Key Question 4:

• Does mycophenolate mofetil reduce relapse rates and cause fewer side effects compared to calcineurin inhibitors in pediatric nephrotic syndrome patients with steroid dependency or frequent relapses?

**Recommendation**

Mycophenolate mofetil is a viable option for maintaining remission in pediatric patients with steroid-dependent or frequently relapsing nephrotic syndrome. (Grade of recommendation: Weak, Quality of evidence: Low)

**[Clinical considerations]**

In patients at risk for leukopenia, infections, gastrointestinal disturbances, and other side effects, it is essential to carefully monitor for potential drug-related side effects when using mycophenolate mofetil.



► **Considerations for selecting CYC**

- **Efficacy**
  - relapse reduction
  - maintaining remission effects in FR/SDNS
- **Risks**
  - gonadal toxicity and leukopenia
- **Insufficient evidence**
  - no clear superiority or safety advantage over CNIs
- **Consider in prepubertal patients**
- **Provide thorough counseling on potential benefits and harms**



.....

.....

.....

.....

.....

.....

.....

► **Key Question 5:**

- **Is cyclophosphamide more effective and safer than calcineurin inhibitors in reducing relapse in pediatric and adolescent patients with frequently relapsing or steroid-dependent nephrotic syndrome?**

**Recommendation**

Cyclophosphamide is often utilized to decrease relapses and sustain remission in children and adolescents suffering from frequently relapsing or steroid-dependent nephrotic syndrome.

(Grade of recommendation: Weak, Quality of evidence: Low)

**[Clinical considerations]**

It is important to obtain informed consent from both the patients and guardians regarding potential drug-related side effects, particularly the risk of gonadal toxicity in adolescent patients, before administering the medication. Monitoring for side effects should be conducted while ensuring that the drug does not exceed the maximum concentration level.



.....

.....

.....

.....

.....

.....

.....

► **Summary**

1. In pediatric patients with primary nephrotic syndrome, there is no significant difference in remission rates and drug-related side effects between deflazacort and prednisolone. Therefore, either drug may be selected based on clinical circumstances and medication costs.
2. The recommended initial treatment for pediatric nephrotic syndrome patients is to administer oral prednisolone for 8–12 weeks. Additional long-term use is not advised.
3.
  1. It is recommended to administer oral prednisolone at a daily dose of 60 mg/m<sup>2</sup>/day or 2 mg/kg/day (maximum 60 mg/day) to pediatric patients with nephrotic syndrome at the onset of the condition.
  2. It is recommended to administer oral prednisolone at a daily dose of 60 mg/m<sup>2</sup>/day or 2 mg/kg/day (maximum 60 mg/day) to pediatric patients with nephrotic syndrome during relapse.
4. Mycophenolate mofetil is a viable option for maintaining remission in pediatric patients with steroid-dependent or frequently relapsing nephrotic syndrome.
5. Cyclophosphamide is often utilized to decrease relapses and sustain remission in children and adolescents suffering from frequently relapsing or steroid-dependent nephrotic syndrome.



.....

.....

.....

.....

.....

.....

.....



► **Upcoming Guideline Topic:**  
**Steroid-resistant nephrotic syndrome**

1. **Genetic Testing**  
- Does performing genetic testing improve complications and prognosis compared to not testing?
2. **Renin–Angiotensin System (RAS) Blockade**  
- Does RAS blockade improve outcomes and reduce complications compared to no treatment?
3. **Tacrolimus vs. Cyclosporine**  
- In patients without identified genetic mutations, does Tac provide better prognosis with fewer side effects than CSA?
4. **Rituximab**  
- In patients unresponsive to CNIs, is rituximab more effective and safer than other immunosuppressive therapies?



.....  
.....  
.....  
.....  
.....  
.....  
.....

► **Conclusions**

- **Evidence-based recommendations for pediatric SSNS in Korea**  
- five Key recommendations
- **Purpose**  
- clinical decision-making  
- improve outcomes (survival, kidney function)  
- reduce drug-related side effects
- **Limitation**  
- not all recommendations supported by high-certainty evidence  
- need for well-designed RCTs
- **Provides practical clinical framework for the healthcare setting in Korea**



.....  
.....  
.....  
.....  
.....  
.....  
.....

## How to delay and how to treat chronic kidney disease in children

**Yusuke Okuda, Kenji Ishikura**

Department of Pediatrics, Kitasato University School of Medicine

Treatment and supportive care strategies for children with chronic kidney disease (CKD) vary according to the underlying etiology. Disease-specific management should be prioritized when possible, as certain conditions such as glomerulonephritis and idiopathic nephrotic syndrome are potentially treatable. However, many underlying disorders lack definitive therapies, and management often focuses on delaying CKD progression.

Conventional treatment including corticosteroids, immunosuppressive agents, and renin-angiotensin system inhibitors (RASi) remain common in the management of IgA nephropathy. Novel strategies targeting B cells or the complement system are under development. Complement inhibition is also a promising treatment option for other complement-mediated kidney diseases. In nephrotic syndrome, several clinical trials conducted over the past decade have expanded therapeutic options and improved clinical outcomes.

For CKD caused by conditions without disease-specific therapies, including congenital anomalies of the kidney and urinary tract (CAKUT), Alport syndrome, and nephronophthisis/polycystic kidney disease (PKD), RASi is a key drug for delaying CKD progression. In children with CKD and hypertension, strict blood pressure control using RASi is recommended. Several studies support the renoprotective effects of RASi in Alport syndrome. However, its efficacy in CAKUT remains uncertain. While robust evidence supports the use of sodium-glucose cotransporter-2 inhibitors in adults, data in pediatric populations are limited. A clinical trial for children and young adults with Alport syndrome is currently underway. Tolvaptan is widely used to delay CKD progression in adults with ADPKD, but evidence is scarce in children.

The therapeutic landscape for CKD is evolving rapidly; however, evidence in children remains insufficient. Bridging this evidence gap through dedicated pediatric studies will facilitate the appropriate application of adult findings to children with CKD. Moreover, pediatric-onset CKD has characteristics unique to children, underscoring the need to establish evidence specific to the pediatric population.





# Oral Presentation



O-1

## Clinical utility of targeted genome sequencing in previously undiagnosed cases of Alport syndrome

**Asahi Yamamoto<sup>1,2</sup>, China Nagano<sup>1</sup>, Shuhei Aoyama<sup>1</sup>, Yuka Kimura<sup>1</sup>, Yuta Inoki<sup>1</sup>,  
Nana Sakakibara<sup>1</sup>, Tomoko Horinouchi<sup>1</sup>, Tomohiko Yamamura<sup>1</sup>, Shingo Ishimori<sup>1</sup>,  
Takayuki Okamoto<sup>2</sup>, Kandai Nozu<sup>1</sup>**

<sup>1</sup>Department of Pediatrics, Kobe University Graduate School of Medicine, <sup>2</sup>Department of Pediatrics, Hokkaido University Graduate School of Medicine

**Backgrounds:** Alport syndrome is a hereditary glomerular disorder caused by pathogenic variants in COL4A3, COL4A4, or COL4A5, which encode type IV collagen. Clinically, it is characterized by hematuria, progressive kidney dysfunction, sensorineural hearing loss, and ocular abnormalities. Identification of the causative gene is essential for prognosis prediction, genetic counseling, and donor selection. At the time of the initial genetic evaluation, genetic diagnosis in our laboratory relied primarily on Sanger sequencing limited to exons and flanking intronic regions of COL4 genes. We therefore reanalyzed previously undiagnosed cases using targeted genome sequencing with a custom-designed panel covering all exons and introns, including deep intronic regions, of COL4A3, COL4A4, and COL4A5, together with additional genes associated with Alport-like disorders.

**Case:** Fifteen undiagnosed cases were included, in whom prior genetic analyses were primarily based on Sanger sequencing of COL4A3, COL4A4, and COL4A5. Based on initial clinical data, the cohort consisted of 15 patients (6 males and 9 females; 7 pediatric and 8 adult cases). Urinalysis data were available for 14 patients; data were unavailable for one patient due to prior kidney transplantation. All had hematuria, including gross hematuria in 8 patients, and 13 patients had proteinuria. Two patients required renal replacement therapy. Extrarenal manifestations included ocular abnormalities in one and hearing loss with suspected ocular abnormalities in another. A family history of urinary abnormalities was present in 12 patients, and a family history of dialysis in 6 patients. Targeted genome sequencing identified variants suspected to be pathogenic in 8 patients. Exonic variants in COL4A5 were detected in two patients, including one with somatic mosaicism, while variants in MYH9 were identified in one patient. In addition, deep intronic variants in COL4A5 predicted by SpliceAI to induce cryptic exon formation were identified in 5 patients.

**Conclusions:** Targeted genome sequencing enabled the identification of disease-associated variants in a substantial proportion of previously undiagnosed cases clinically suspected of Alport syndrome, particularly



deep intronic variants and variants in non-COL4 genes that were not detectable using conventional Sanger-based analyses.

**Points of discussion:** Exon- and intron-inclusive targeted genome sequencing may be a practical and time- and cost-effective diagnostic option for patients clinically suspected of Alport syndrome.

**Keywords:** Alport syndrome, genetic diagnosis, targeted genome sequencing, COL4A5, deep intronic variant

## O-2

## When Chronic Tubulointerstitial Nephropathy Is Not Inflammatory: Reanalysis of Genome Sequencing Identifies ANKS6 Variants in Early-Onset ESKD

**Naye Choi<sup>1,2</sup>, Hyuna Lee<sup>3</sup>, Ji Hyun Kim<sup>2,4</sup>, Jung Sue Kim<sup>5</sup>, Hae Il Cheong<sup>6</sup>,  
Hee Gyung Kang<sup>1,2</sup>, Yo Han Ahn<sup>1,2</sup>**

<sup>1</sup>Department of Pediatrics, Seoul National University Children's Hospital, Seoul, Korea, <sup>2</sup>Department of Pediatrics, Seoul National University College of Medicine, Seoul, Korea, <sup>3</sup>Department of Pediatrics, Ajou University Hospital, Suwon, Korea, <sup>4</sup>Department of Pediatric, Seoul National University Bundang Hospital, Seongnam-si, Korea, <sup>5</sup>Department of Pediatrics, Cheongju St. Mary's Hospital, Cheongju, Korea, <sup>6</sup>Department of Pediatrics, Seoul Red Cross Hospital, Seoul, Korea

**Background:** Nephronophthisis (NPHP) is a major genetic cause of pediatric end-stage kidney disease (ESKD) and may present histologically as chronic tubulointerstitial nephropathy with tubular dilatation, mimicking inflammatory tubulointerstitial nephritis (TIN). ANKS6 (NPHP16) is a ciliopathy gene associated with NPHP-like kidney disease and reported extrarenal involvement.

**Case Presentation:** A boy developed progressive kidney dysfunction in infancy and underwent kidney biopsy at 7 months of age showing chronic tubulointerstitial nephropathy with tubular dilatation. Given concern for TIN, oral corticosteroid therapy was initiated with minimal clinical response, and the patient progressed to ESKD requiring peritoneal dialysis, followed by kidney transplantation at 4 years of age. Native nephrectomy later demonstrated diffuse, small cystic changes throughout the renal parenchyma. The patient had additional multisystem findings including recurrent unexplained aminotransferase elevation without definitive fibrosis on prior liver biopsy, hemolytic anemia, microcephaly with mild developmental delay, and ascending aortic dilatation in the setting of a small aortic annulus.

Prior chromosomal microarray, mitochondrial testing, and trio exome analysis were non-diagnostic. Reanalysis of trio genome sequencing identified two ANKS6 variants (c.360-992G>C and c.1093A>G), currently classified as variants of uncertain significance, raising suspicion for autosomal recessive ANKS6-related nephronophthisis (NPHP16).

**Conclusion:** This case highlights how NPHP-spectrum ciliopathies—particularly ANKS6-associated disease—can be misclassified as chronic TIN on histology, potentially prompting empiric immunosuppression with limited benefit. Systematic early genetic testing and periodic reanalysis may reduce diagnostic delay and better



contextualize multisystem findings, including hepatobiliary abnormalities and cardiovascular involvement.

**Points of discussion:**

- 1) Was empiric steroid therapy appropriate for “r/o TIN,” and how often are genetic kidney diseases mis-labeled as TIN?
- 2) Can ANKS6 explain the kidney pathology and the extrarenal features of this patient?

O-3

## Is this a case of IgA nephropathy, Alport syndrome or Frasier syndrome?

**Fang Yang<sup>1</sup>, Shuting Peng<sup>1</sup>, Zhengye Tian<sup>1</sup>, Ding Liu<sup>1</sup>, Jieying Feng<sup>1</sup>, Shuling Yue<sup>2</sup>**

<sup>1</sup>Department of Pediatric nephrology, the First Affiliated Hospital of Jinan University, Guangzhou, China,

<sup>2</sup>Department of Pathology, Guangzhou Kingmed clinical Laboratory, China

**Backgrounds:** With the widespread application of genetic testing technology, more and more diseases are being diagnosed. Currently, we cannot change these pathogenic genes. Do we still need to treat these diseases based on pathological changes?

**Case:** The patient Chen xx, 1 year 7 months old, male, was admitted to our hospital on August 22, 2022 due to "Swelling of both eyelids and lower limbs for 2 months". Diagnosed with nephrotic syndrome by other hospitals and treated with sufficient prednisone for over a week before admission. Physical examination: BP: 98/68mmHg, body weight: 10Kg. Swelling in both eyelids and lower limbs, no abnormalities found on cardiopulmonary auscultation. Abdominal distension, no enlargement of the liver and spleen, swelling of the scrotum, malformation of the external genitalia, split scrotum, and curvature of the glans penis towards the abdomen.

**2022.08.23 Urinalysis:** protein 1g/L, the rest is normal. Serum creatinine: 47umol/L, Serum Urea nitrogen: 12.67mmol/L, Serum albumin: 19.7g/L, Total cholesterol: 17.75mmol/L, TG: 4mmol/L, HDL-C: 2.29mmol/L, LDL-C: 8.88mmol/L, C3 and C4 are normal. 24-hour urinary protein: 65,20mg/kg. Continue to administer prednisone treatment to the patient, but urine protein remains positive.

Renal biopsy(2022.09.08: light microscopy Results: Five glomeruli were found without glomerulosclerosis, with two glomeruli suspected of segmental sclerosis. The other glomerular mesangial cells and stroma proliferate, the epithelial cells of renal tubules become vacuolar and granular, focal atrophy, small focal inflammatory cells infiltrate the renal interstitium with fibrosis, and a small number of foam cells can be seen. Immunofluorescence: IgA diffuse, nodular mesangial area with punctate deposition. IgG(-); IgA(++); IgM(+); C3(++); C1q(-); Fib(-); ALB(-); IgG1(-); IgG2(-); IgG3(-); IgG4(-)The positive control of  $\alpha$  1 is normal, the expression of  $\alpha$  3 in glomerular basement membrane and renal tubular basement membrane is normal, the expression of  $\alpha$  4 in glomerular basement membrane is normal, the expression of  $\alpha$  5 in glomerular basement membrane is



segmental weakened, and the expression of renal tubular basement membrane is normal. Electron microscopy Results: The thickness of the glomerular basement membrane varies, with a thickness of about 170-650nm. The dense layer of the basement membrane is thickened, partially torn and spider web like, with extensive fusion of the foot processes. Electron dense deposition can be seen in the mesangial area, and in some cases, electron dense deposition can be seen in the basement membrane. The morphology suggests Alport syndrome.

### Pathological Diagnosis:

1. Consistent with IgA nephropathy, mesangial proliferation with occasional segmental sclerosis in a few glomeruli.
2. Electron microscopy reveals glomerular basement membrane rupture and splitting, with Alport syndrome not ruled out.

Genetic testing results(2022.09.11): WT1 c.1447+4C>T heterozygous variation. Father, mother, and two sisters have no mutation at this locus of the gene.

The chromosomal karyotype of the patient : 46XY.

**Conclusions:** A 1 year 7 months old boy with edema and massive proteinuria as the main clinical manifestations, accompanied by perineal hypospadias. Pathological Diagnosis of the kidney biopsy: IgA nephropathy, with Alport syndrome not ruled out. Genetic testing Results: WT1 c.1447+4C>T heterozygous variation. The chromosomal karyotype of the patient : 46XY.

### Points of discussion :

1. Can this patient be diagnosed with both Frasier syndrome and IgA nephropathy simultaneously?
2. Genetic testing Results: WT1 c.1447+4C>T heterozygous variation. Why the Renal biopsy show the thickness of the glomerular basement membrane varies, partially torn and spider-web like, the expression of  $\alpha 5$  in glomerular basement membrane is segmental weakened ?
3. This child presents with mass proteinuria clinically, impaired renal function, and pathological findings of IgA and C3 deposition in the mesangial area. Mesangial and stromal cell proliferation, as well as extensive fusion of the foot processes. What are the treatment recommendations?
4. This child has a higher risk of developing gonadal tumors. Is it recommended to perform prophylactic gonadectomy on this child?

**Keywords:** Frasier syndrome, IgA nephropathy, Alport syndrome, Genetic testing, diagnosis, treatment

O-4

## Utility of anti-nephrin autoantibody-to-IgG ratio in autoimmune podocytopathies

Yoko Shirai<sup>1</sup>, Kenichiro Miura<sup>1</sup>, Keiichi Takizawa<sup>2</sup>, Yutaka Harita<sup>2</sup>, Etsuko Tanaka<sup>3</sup>, Kiyohiko Hotta<sup>4</sup>, Saori Nishio<sup>5</sup>, Motoshi Hattori<sup>1</sup>

<sup>1</sup>Department of Pediatric Nephrology, Tokyo Women's Medical University, Tokyo, Japan, <sup>2</sup>Department of Pediatrics, the University of Tokyo, Tokyo, Japan, <sup>3</sup>Department of Pediatrics, Faculty of Medicine, University of Miyazaki, <sup>4</sup>Department of Renal and Genitourinary Surgery, Faculty of Medicine, Hokkaido University, <sup>5</sup>Department of Hemodialysis and Apheresis, Hokkaido University Hospital

**Backgrounds:** Anti-nephrin autoantibodies have been implicated in autoimmune podocytopathies, including minimal change disease and focal segmental glomerulosclerosis (FSGS). However, ELISA methods and cut-off values are not standardized, and antibody levels may be underestimated in nephrotic syndrome because of urinary IgG loss. We hypothesized that the anti-nephrin autoantibody-to-IgG ratio might better reflect disease activity. We therefore analyzed serial changes in this ratio in two patients with steroid-resistant nephrotic syndrome (SRNS) and two patients with post-transplant recurrent FSGS (rFSGS).

**Case:** Both SRNS patients achieved complete remission with immunosuppressive therapy and/or plasma exchange. In the rFSGS cases, recurrence occurred on postoperative days 1 and 76. One patient progressed to graft failure, whereas the other achieved remission after steroid pulse therapy, rituximab administration, and plasma exchange. All patients showed IgG deposition colocalized with nephrin on biopsy. In all cases, during nephrotic-range proteinuria, anti-nephrin autoantibody titers fluctuated or became negative, whereas the anti-nephrin autoantibody-to-IgG ratio remained consistently positive. In one rFSGS case, antibody titers became negative after prophylactic plasma exchange before kidney transplantation, but the anti-nephrin autoantibody-to-IgG ratio remained positive, followed by immediate severe post-transplant recurrence. Similarly, another patient showed a negative anti-nephrin autoantibody titer at post-transplant recurrence, while the anti-nephrin autoantibody-to-IgG ratio was positive. Both measurements became negative after remission. In all patients, anti-nephrin autoantibodies fluctuated between positive and negative during nephrotic-range proteinuria but were consistently positive during subnephrotic proteinuria at all time points. In contrast, the anti-nephrin autoantibody-to-IgG ratio remained positive during all episodes of proteinuria and turned negative after remission.

**Conclusions:** Anti-nephrin autoantibodies are considered markers of disease activity; however, neph-



rotic-range proteinuria and plasma exchange may reduce detectable antibody levels because of IgG loss. In our cohort, antibody titers alone did not reliably reflect disease status, particularly during heavy proteinuria or after plasma exchange. By contrast, the anti-nephrin autoantibody-to-IgG ratio remained positive during active disease and turned negative in remission.

**Points of discussion:** These findings suggest that anti-nephrin autoantibody-to-IgG ratio may better reflect disease activity than antibody titers alone. When interpreting anti-nephrin autoantibody results, the degree of proteinuria and treatment timing should be considered. The anti-nephrin autoantibody-to-IgG ratio may help avoid false-negative interpretations in nephrotic syndrome.

**Keywords:** nephrotic syndrome, anti-nephrin autoantibodies, IgG, ELISA

O-5

## Lupus Nephritis as a Manifestation of TNFAIP3-Related A20 Haploinsufficiency

Hannah Yoon, Na Ye Choi, Yo Han Ahn, Hee Kyung Kang, Seong Heon Kim

Department of Pediatrics, Seoul National University Children's Hospital, Seoul, Korea

**Background:** Systemic lupus erythematosus (SLE) is a heterogeneous multisystem autoimmune disease, and early-onset cases are more likely to have a strong genetic contribution. Monogenic immune dysregulation, affecting pathways such as NF- $\kappa$ B signaling, can produce lupus-like autoimmunity and severe organ involvement at a young age. Although rare among monogenic lupus etiologies, TNFAIP3-related A20 haploinsufficiency (HA20) can be an underlying cause of pediatric lupus nephritis.

**Case summary:** A 6-year-old boy presented with early-onset glomerulonephritis manifested by heavy proteinuria, hematuria, and systemic inflammation. Initial serologic evaluation was atypical for systemic lupus erythematosus, with normal C3 levels (101 mg/dL) despite low C4 (7 mg/dL), and negative anti-double-stranded DNA, anti-Sm, and rheumatoid factor tests. Antinuclear antibodies were present at high titer (1:640, speckled pattern), with positivity for lupus anticoagulant, anticardiolipin IgG, and anti- $\beta$ 2-glycoprotein I IgG, while anticardiolipin IgM was negative. Renal biopsy revealed diffuse proliferative lupus nephritis (ISN/RPS class IV-G) with high activity. The patient was treated with high-dose corticosteroids followed by induction therapy with intravenous cyclophosphamide and rituximab, achieving complete renal remission. Renal remission was maintained for more than 2 years, including after discontinuation of immunosuppressive therapy. Initial serum IgG level prior to rituximab was mildly decreased (414 mg/dL) and declined further after treatment (up to 296 mg/dL), necessitating subsequent intravenous immunoglobulin replacement therapy. While lupus nephritis remained in sustained remission, recurrent infections and mucocutaneous inflammatory manifestations developed during follow-up. Genetic testing that had been performed for suspected early-onset glomerulonephritis identified a heterozygous frameshift mutation in TNFAIP3 (c.986del; p.Lys329SerfsTer14). Family segregation analysis demonstrated paternal inheritance with variable expressivity.

**Conclusion:** Early-onset lupus nephritis may occur in TNFAIP3-related A20 haploinsufficiency (HA20). Rituximab achieved sustained complete renal remission even after stopping immunosuppression due to in-



fections, while persistent hypogammaglobulinemia was associated with ongoing Behçet-like symptoms, supporting early consideration of monogenic immune dysregulation and individualized, infection-conscious management.

**Points of discussion:**

1. How can immune-complex lupus nephritis arise in TNFAIP3 haploinsufficiency?
2. Is conventional immune-complex-driven LN therapy theoretically appropriate in HA20-associated LN?

O-6

## Incident IgA Nephropathy shortly followed with seroconversion of positive anti-GBM antibodies and rapid progression of glomerulonephritis in a Chinese boy: same disease or overlapped process?

**Xu Zhang, Fengjie Yang, Shiyi Wu, Yu Zhang, Jianhua Zhou**

Department of Pediatrics, Tongji Hospital, Tongji Medical College, Huazhong University of Science & Technology, Wuhan, 430030, Hubei Province, China

**Backgrounds:** Anti-glomerular basement membrane (anti-GBM) disease is a rare, aggressive autoimmune disorder that seldom coexists with IgA nephropathy (IgAN). The development of anti-GBM disease secondary to IgAN in pediatric patients—specifically with confirmed seroconversion—is exceptionally rare. We present a case of a 14-year-old boy who developed anti-GBM disease shortly after an initial diagnosis of IgAN.

**Case:** A 14-year-old male presented with a 10-day history of gross hematuria. Initial evaluation showed normal renal function and negative anti-GBM antibodies. The initial renal biopsy confirmed IgAN (Lee grade V; Oxford classification M0E0S0T1-C2). Despite standardized immunosuppressive therapy, his renal function deteriorated rapidly four months later, with serum creatinine (Scr) surging from 65 to a peak of 665  $\mu\text{mol/L}$ . Repeat serological testing revealed a significant seroconversion of anti-GBM antibodies from negative to strongly positive ( $>8.0$  AI). A second renal biopsy demonstrated devastating progression, with 100% fibrocellular crescent formation and intense linear IgG deposition along the glomerular capillary walls. The patient received an intensified regimen consisting of plasmapheresis, hemodialysis, and cyclophosphamide pulse therapy. Following treatment, his anti-GBM antibodies turned negative, and renal function stabilized without dialysis, though it did not return to the pre-morbid baseline.

**Conclusions:** We report a pediatric male case in whom anti-glomerular basement membrane disease developed secondarily during the clinical course of IgA nephropathy. This case strongly suggests that in patients with newly diagnosed chronic glomerulonephritis, such as IgA nephropathy, a high index of suspicion for concurrent autoimmune diseases including anti-glomerular basement membrane disease should be maintained when rapid progression of glomerulonephritis occurs.

**Points of discussion:**

1. Immunopathogenesis of IgAN and anti-GBM nephritis.



2. Overlap of IgAN and anti-GBM disease were extremely rare.

In-depth analysis of the causes and mechanisms underlying the sequential occurrence of IgAN and anti-GBM nephritis in this patient.

**Keywords:** Anti-glomerular basement membrane disease; IgA nephropathy; Pediatric; Rapidly progressive glomerulonephritis.

O-7

## High-sensitivity anti-nephrin autoantibody assay predicts steroid resistance and glomerulonephritis in childhood idiopathic nephrotic syndrome

**Tomoko Horinouchi<sup>1</sup>, Masaya Muto<sup>2</sup>, Yuta Inoki<sup>1</sup>, Natsumi Yamamura<sup>3</sup>, Koichi Kamei<sup>4</sup>, Rika Fujimaru<sup>5</sup>, Miwa Goto<sup>6</sup>, Hiroki Miyano<sup>7</sup>, Rie Kuroki<sup>8</sup>, Tomoo Kise<sup>9</sup>, Hideki Ban<sup>10</sup>, Kazuki Tanaka<sup>11</sup>, Riku Hamada<sup>12</sup>, Yumiko Sakai<sup>2</sup>, Amane Harada<sup>2</sup>, China Nagano<sup>1</sup>, Kandai Nozu<sup>1</sup>, Kazumoto Iijima<sup>1</sup>**

<sup>1</sup>Kobe University, <sup>2</sup>Systemex Corporation, <sup>3</sup>Osaka Women's and Children's Hospital, <sup>4</sup>National Center for Child Health and Development, <sup>5</sup>Osaka City General Hospital, <sup>6</sup>University of Yamanashi, <sup>7</sup>Juntendo University Nerima Hospital, <sup>8</sup>Japanese Red Cross Fukuoka Hospital, <sup>9</sup>Okinawa Prefectural Nanbu Medical Center & Children's Medical Center, <sup>10</sup>Japanese Red Cross Kumamoto Hospital, <sup>11</sup>Aichi Children's Health and Medical Center, <sup>12</sup>Tokyo Metropolitan Children's Medical Center

**Backgrounds:** Although several studies have reported the involvement of anti-nephrin autoantibodies in nephrotic syndrome (NS), their clinical significance and association with disease course remain insufficiently understood.

**Case:** From July 2024 to June 2025, children diagnosed with idiopathic NS across Japan were prospectively enrolled. Circulating anti-nephrin autoantibodies were measured before prednisolone administration using an automated immunoassay on the Automated Immunoassay System HISCL-5000 (Systemex). The cutoff value for positivity was defined as >807 SU/mL based on acute non-kidney disease controls, and antibody levels  $\geq 10,000$  SU/mL were defined as high-titer positive. A total of 63 patients (45 males, 18 females; median age 70.5 months [34.5–141]) with newly diagnosed idiopathic NS were enrolled. Outcomes were distributed as follows: Positive group (n=50): 49 steroid sensitive nephrotic syndrome (SSNS), 1 steroid resistant nephrotic syndrome (SRNS), 0 glomerulonephritis (GN); High-titer positive group (n=6): 1 SSNS, 5 SRNS, 0 GN; Negative group (n=7): 0 SSNS, 3 SRNS, 4 GN.

**Conclusions:** Patients in the high-titer positive and negative groups had a significantly higher likelihood of progressing to SRNS or GN compared with those in the positive group ( $P < 0.0001$ ). Serum BUN levels were significantly higher in the high-titer positive group compared with the positive group ( $P = 0.01$ ); however, no significant differences were observed among the three groups with respect to age at onset or other laboratory findings.

**Points of discussion:** All SSNS cases were positive for anti-nephrin autoantibodies, suggesting a strong in-



volvement of these antibodies in disease pathogenesis. Incorporating anti-nephrin autoantibody profiling into the initial diagnostic workup may contribute to risk stratification and the development of personalized treatment strategies in pediatric NS.

**Keywords:** anti-nephrin autoantibody, childhood idiopathic nephrotic syndrome

O-8

## Two Infants with TSC and Early Renal Cysts: Implications for Genomic Evaluation

Hyun Seo Kim, Jung Hye Byeon, Juyoung Lee, Dong Hwa Yang, Eujin Park

Department of Pediatrics, Korea University College of Medicine

**Background:** Tuberous sclerosis complex (TSC) frequently involves the kidney, and renal cysts may occur in patients with TSC2-related disease. However, early renal cysts detected during infancy may also suggest TSC2-PKD1 contiguous gene syndrome (CGS), which is associated with rapid cyst progression and poorer renal prognosis. Determining when to escalate genomic evaluation in infants with TSC2 phenotype and renal cysts remains a clinical challenge.

**Case Comparison:** We present two infants with clinically diagnosed TSC and early renal cysts who underwent different genomic evaluation pathways.

In Case 1, targeted exome sequencing (TES) failed to identify a pathogenic TSC2 variant despite clinical features consistent with TSC. Because renal cysts were detected during infancy and CGS was suspected, whole-genome sequencing (WGS) was performed. WGS identified a heterozygous likely pathogenic 21kb inversion involving the TSC2 locus without PKD1 involvement, thereby excluding CGS. Serial renal ultrasonography demonstrated stable cyst burden during follow-up.

In Case 2, TES detected a pathogenic TSC2 variant. However, a single renal cyst detected at birth showed rapid progression to multiple cysts on short-interval ultrasonographic follow-up. Because CGS was suspected, WGS was additionally performed and revealed a large deletion involving both TSC2 and PKD1, confirming CGS.

**Conclusion:** These two infant cases illustrate distinct roles of WGS in TSC-associated renal cysts: detection of structural variants when TES is negative and confirmation or exclusion of CGS when TES identifies a TSC2 variant. Renal cyst trajectory during infancy may guide genomic escalation and inform renal prognosis in clinical practice.

### Points of discussion

- 1) Cost-effective genomic evaluation in TSC patients with renal cysts
- 2) Future treatment implications in CGS



## Abernethy malformation type Ib combined with membranoproliferative glomerulonephritis: a case received liver transplantation

**Anna Shen<sup>1</sup>, Weihua Zheng<sup>1</sup>, Wenyan Huang<sup>1</sup>, Yun Cui<sup>2</sup>, Yucai Zhang<sup>2</sup>, Yulin Kang<sup>1</sup>**

<sup>1</sup>Department of Nephrology and Rheumatology, Shanghai Children's Hospital, Shanghai Jiao Tong University School of Medicine, Shanghai, China, <sup>2</sup>Department of Critical Care Medicine, Shanghai Children's Hospital, Shanghai Jiao Tong University School of Medicine, Shanghai, China

**Backgrounds:** Abernethy malformation is a rare congenital vascular disorder defined by the absence or marked hypoplasia of the portal vein, leading to portosystemic shunting and consequent bypass of hepatic filtration. Although its metabolic and immunological sequelae—such as hepatic encephalopathy and pulmonary involvement—have been well described, renal complications remain poorly understood. To date, fewer than ten cases have documented an association between congenital portosystemic shunts and glomerular disease, with histological findings including IgA nephropathy, mesangioproliferative glomerulonephritis, and membranoproliferative glomerulonephritis (MPGN).

**Case:** We describe a 13-year-old boy who, following an episode of diarrheal illness, developed severe anemia, pneumonia, and nephrotic-range proteinuria (14.18 g/24h). Imaging studies revealed Abernethy malformation type Ib, characterized by complete agenesis of the portal vein with direct shunting into the inferior vena cava. Renal biopsy disclosed MPGN accompanied by a full-house immunofluorescence pattern (IgG, IgA, IgM, C3, C4, and C1q) and hypocomplementemia. After liver transplantation, proteinuria decreased sharply to 1.2 g/24h within one month, alongside normalization of complement levels and hemoglobin. This constituted a partial remission of nephrotic syndrome, achieved without escalation of immunosuppressive therapy.

**Conclusions:** This case substantiates a causal link between congenital portosystemic shunting and MPGN, showing that reinstating portal venous flow via liver transplantation can prompt rapid regression of established glomerular injury. These observations challenge the necessity of combined liver-kidney transplantation in similar scenarios and suggest that vascular imaging for Abernethy malformation should be considered in individuals with unexplained glomerulonephritis—particularly those presenting with hypocomplementemia or hepatic abnormalities.

**Points of discussion:** (1) The pathophysiological mechanisms driving renal injury in Abernethy malformation,

including impaired hepatic clearance of gut-derived immune complexes and microbial antigens, complement dysregulation, and possible hemodynamic factors; (2) The potential contribution of gut microbiota dysbiosis to glomerular damage in the setting of portal shunting; (3) Diagnostic implications and the importance of considering Abernethy malformation in patients with atypical presentations of nephrotic syndrome; (4) Therapeutic considerations regarding liver transplantation as a definitive intervention for both hepatic and renal disease manifestations; (5) Study limitations, notably the lack of post-transplant renal biopsy to histologically confirm remission.

**Keywords:** Membranoproliferative glomerulonephritis; Abernethy malformation; Nephrotic syndrome; Congenital extrahepatic portosystemic shunt





# Poster Presentation





P1-1

## An Unusual Cause of Acute Kidney Injury with Severe Lactic Acidosis: Kidney Infiltration by B-Cell Lymphoblastic Lymphoma in a Pediatric Patient

Soo Kyung Lee<sup>1</sup>, Hyoung Soo Choi<sup>2,3</sup>, Ji Hyun Kim<sup>2,3</sup>

<sup>1</sup>Department of Pediatrics, Seoul National University Children's Hospital, Seoul, South Korea, <sup>2</sup>Department of Pediatrics, Seoul National University Bundang Hospital, Seongnam, South Korea, <sup>3</sup>Department of Pediatrics, Seoul National University College of Medicine, Seoul, South Korea

**Background:** Acute kidney injury (AKI) is often accompanied by metabolic acidosis; however, persistent severe lactic acidosis is rarely explained by AKI alone. In such cases, alternative systemic or metabolic etiologies should be considered. Here, we report a pediatric case of AKI with severe lactic acidosis, without overt hematologic abnormalities, ultimately diagnosed as kidney infiltration by B-cell lymphoblastic lymphoma.

**Case:** A previously healthy 14-year-old girl presented with a 1-month history of nausea, vomiting, weight loss, and polydipsia with high urine output. Initial evaluation revealed severe high anion gap lactic acidosis (pH 7.013, HCO<sub>3</sub><sup>-</sup> 4.6 mmol/L, lactate 17 mmol/L), with AKI (BUN/Cr 38/1.60 mg/dL, eGFR 42 mL/min/1.73 m<sup>2</sup>). Laboratory findings also showed tubular dysfunction, including hypokalemia (3.0–3.2 mmol/L) with renal potassium wasting and markedly increased urine  $\beta$ 2-microglobulin (31.7 mg/L). Macrocytic anemia (Hb 7.6–8.6 g/dL, MCV 100–110 fL) without folate or vitamin B12 deficiency was present, while other hematologic indices were largely unremarkable, including a normal peripheral blood smear and only marginal lactate dehydrogenase elevation (284 IU/L; reference range 100–225 IU/L). Kidney ultrasonography revealed bilateral nephromegaly (right kidney 15.0 cm, left kidney 13.3 cm) with increased parenchymal echogenicity. Despite conservative management with hydration and bicarbonate administration, lactic acidosis persisted. Extensive evaluation for infectious, pharmacologic, and metabolic causes was unrevealing. Given the constellation of unexplained AKI, persistent lactic acidosis, tubular dysfunction, bilateral nephromegaly, and anemia, a kidney biopsy was performed, revealing diffuse infiltration of B lymphoblasts. The diagnosis of B-cell lymphoblastic lymphoma was subsequently confirmed by bone marrow biopsy. Following initiation of chemotherapy, lactic acidosis resolved rapidly, with subsequent improvement in kidney function.

**Conclusions:** This case demonstrates that severe lactic acidosis may represent a tumor-related metabolic manifestation of lymphoma rather than a direct consequence of AKI. Because serum lactate is not routinely as-



sessed in pediatric AKI, its measurement should be considered in patients with severe and persistent metabolic acidosis and atypical features, including nephromegaly. Despite the absence of overt hematologic abnormalities, early kidney biopsy prompted by atypical AKI features was pivotal in establishing the diagnosis and enabling timely identification of lymphoma.

**Points of discussion:**

- 1) What are the pathophysiologic mechanisms underlie severe type B lactic acidosis in pediatric patients with AKI in the absence of hypoxia or sepsis?
- 2) When should kidney biopsy be considered in pediatric AKI accompanied by unexplained metabolic abnormalities, and how does early histologic diagnosis influence clinical outcomes?

P1-2

## A Case of Distal Renal Tubular Acidosis Diagnosed from Poor Weight Gain in a Female Infant

Koki Ota, Yuji Moto, Junichiro Araki, Shingo Niimi, Keishirou Houjou, Yuusuke Hiyoshi, Yasuhiro Yoshida, Satoko Kurata, Seiji Tanaka

Department of Pediatrics and Child Health, Kurume University

**Backgrounds:** Causes of poor weight gain in infants are diverse. Distal renal tubular acidosis (dRTA) is an extremely rare disease affecting one in 600,000 individuals. We report an infant diagnosed with dRTA following poor weight gain. Currently, six genes have been reported, with ATP6V0A4/1B1 and SLC4A1 being the most common. We report the clinical course of the rare FOXI1.

**Case:** A 6-month-old female infant presented with poor feeding and poor weight gain. She exhibited metabolic acidosis with a normal anion gap despite hypokalemia and normal renal function. Urinalysis showed no decrease in urine pH despite acidosis and a positive urine anion gap. Even after furosemide loading, urine pH did not fall below 5.5. Based on impaired urinary acidification, a diagnosis of dRTA was made. Treatment involved correcting hypokalemia followed by acid correction with citrate. Breastfeeding improved, and the infant was discharged. Bilateral sensorineural hearing loss, consanguineous marriage, and a family history of sibling hearing loss raised suspicion of hereditary dRTA. Genetic testing identified FOXI1. FOXI1 is a rare causative gene for dRTA, making awareness of its phenotype important. Furthermore, when considering differential diagnoses for poor weight gain, RTA should be considered; metabolic acidosis should be confirmed via blood gas analysis, and attention should be paid to hearing loss and family history.

**Conclusions:** Consider RTA as a cause of poor weight gain. Additionally, checking for hearing loss during the medical history interview is important.

**Points of discussion:**

Is it possible to identify genes based on phenotypic differences in dRTA?

**Keywords:** Distal renal tubular acidosis, Genotype-phenotype correlation, poor weight gain



P1-3

## Case Report: Infantile Nephropathic Cystinosis

Wei Bai, Xuhui Zhong

Peking University First Hospital

**Backgrounds:** Cystinosis, a lysosomal storage disorder resulting from mutations in the CTNS gene encoding cystinosin, the lysosomal cystine transporter, leads to pathological accumulation of cystine within lysosomes. This progressive accumulation affects multiple organ systems, culminating in significant dysfunction. The infantile form represents the most severe phenotype, with characteristic renal and extrarenal manifestations emerging within the first months of life. This report describes a case of infantile nephropathic cystinosis, highlighting the clinical trajectory, diagnostic challenges, therapeutic interventions, and the critical importance of early disease recognition.

**Case:** A 5-year-7-month-old girl presented with a 4.5-year history of polyuria and glucosuria first noted at 12 months of age. Initial evaluation revealed marked polyuria (daily output exceeding 2000 mL), hyposthenuria, glucosuria, and proteinuria in the absence of edema. Over subsequent years, she developed progressive growth retardation, fair hair and skin pigmentation, accompanied by persistent metabolic acidosis, hypokalemia, hyponatremia, hypophosphatemia, low-molecular-weight proteinuria, and generalized aminoaciduria—consistent with renal Fanconi syndrome. Serial monitoring demonstrated gradually rising serum creatinine, with development of renal anemia and hyperparathyroidism. Genetic analysis revealed a heterozygous deletion of exons 3–5 in the CTNS gene (paternal origin), prompting suspicion of cystinosis-associated Fanconi syndrome. Symptomatic management with sodium bicarbonate, recombinant human erythropoietin, calcitriol, and oral iron dextran failed to halt disease progression.

Upon referral to our institution, examination revealed profound growth failure (height 93.5 cm, weight 13.19 kg, both below the 3rd percentile), characteristic fair complexion with yellowish-tinged hair, mild wrist widening, and genu valgum. Slit-lamp ophthalmologic examination demonstrated extensive corneal crystal deposition bilaterally. Laboratory evaluation confirmed hypothyroidism, and peripheral blood leukocyte cystine content was markedly elevated, definitively establishing the diagnosis of infantile nephropathic cystinosis.

Disease-modifying therapy was initiated with oral cysteamine bitartrate, alongside comprehensive symptomatic management including potassium citrate, sodium bicarbonate, calcitriol, levothyroxine, indomethacin, vitamin AD supplementation, and levocarnitine. At 20-day follow-up, the patient demonstrated catch-up growth (height increase of 2 cm) and improved renal function parameters, with declining serum creatinine.

**Conclusions:** Infantile nephropathic cystinosis manifests early in life with progressive multisystem involvement. Prompt diagnosis and initiation of cystine-depleting therapy, combined with targeted symptomatic management, can favorably impact growth trajectory and renal outcomes, underscoring the imperative for early clinical recognition.

**Points of discussion:**

**1. Early Diagnostic Considerations:** The constellation of renal Fanconi syndrome in early childhood should prompt immediate consideration of cystinosis, particularly when accompanied by extrarenal features including fair pigmentation, photophobia, and growth failure. The presence of corneal crystals on slit-lamp examination provides rapid diagnostic support.

**2. Diagnostic Confirmation:** Elevated leukocyte cystine levels remain the gold standard for diagnosis, while CTNS genotyping provides confirmatory evidence and enables genetic counseling.

**3. Therapeutic Imperatives:** Cysteamine therapy, by depleting intralysosomal cystine, represents the cornerstone of disease-modifying treatment. Early initiation is critical to preserve renal function and delay or prevent extrarenal complications including hypothyroidism, myopathy, and central nervous system involvement. This case demonstrates that even with delayed diagnosis, initiation of cysteamine therapy can yield measurable clinical improvement.

**Keywords:** Infantile cystinosis, CTNS gene, Fanconi syndrome, Cysteamine



P1-4

## Renal Manifestations of Baraitser-Winter Cerebrofrontofacial Syndrome: A Case Report

Yeonhee Lee

Department of Pediatrics, Seoul St. Mary's Hospital, College of Medicine, The Catholic University of Korea, Seoul, South Korea

**Background:** Baraitser-Winter Cerebrofrontofacial syndrome (BWCF), first described by Baraitser and Winter in 1988, is an extremely rare multisystem disorder with fewer than 50 cases reported in the medical literature. The syndrome is characterized by a distinct facial phenotype including iris coloboma, bilateral ptosis, a broad nasal bridge, and prominent medial canthal folds, often accompanied by short stature and intellectual disability. While the clinical spectrum was further expanded by Verloes et al. in a study of 42 patients, infrequent systemic complications, such as renal and urinary tract abnormalities, have also been documented.

**Case:** A 7-year-old female with developmental delay, hearing impairment, and exotropia was referred to the pediatric nephrology clinic for a preoperative evaluation of decreased renal function. Although chromosomal abnormalities involving chromosomes 7 and 14 were noted at birth, she had been managed with a renin-angiotensin-aldosterone system (RAAS) inhibitor (valsartan 10.5 mg) and sodium bicarbonate for chronic proteinuria for seven years. At presentation, her height was below the 10th percentile (115 cm). Laboratory findings confirmed stage 2 chronic kidney disease (CKD) with an eGFR of 68.8–79 mL/min/1.73 m<sup>2</sup>, BUN 24.4 mg/dL, Creatinine 0.69 mg/dL, and significant proteinuria (urine protein-to-creatinine ratio [UPCR] 1.77). After reviewing the venous blood gas analysis (VBGA) results (pH 7.36, pCO<sub>2</sub> 47.9, HCO<sub>3</sub> 26.6), sodium bicarbonate administration was discontinued. Due to persistent proteinuria, the RAAS inhibitor was switched to ramipril, and the dosage was adjusted to minimize. Kidney ultrasonography revealed a small left kidney with increased parenchymal echogenicity, poor corticomedullary differentiation, and a 0.6 cm simple cyst. Historical imaging showed persistent renal hypoplasia, with kidney sizes of 4.5–4.7 cm at age 2 and 5.7–6.0 cm at age 4. Advanced genetic testing identified a 7p22 deletion and 14q trisomy; specifically, ACTB haploinsufficiency led to the definitive diagnosis of BWCF. While the initial renal hypoplasia is likely a manifestation of the syndrome, the progression of renal dysfunction may have been exacerbated by the long-term use of RAAS inhibitors since infancy. The patient has been undergoing regular follow-up for CKD management for the past six years.

**Conclusions:** This case highlights the importance of comprehensive genetic testing when initial clinical findings are non-specific, even in the presence of known chromosomal abnormalities. The report confirms that hypoplastic kidney disease can be a significant systemic manifestation of BWCF resulting from ACTB gene haploinsufficiency. Given the potential for progression to end-stage renal disease (ESRD), vigilant nephrological follow-up is crucial.

**Points of discussion:**

Was the use of ARB (Angiotensin II Receptor Blocker) truly necessary during the neonatal period?



## TSC2-PKD1 Contiguous Gene Syndrome With Rapid Cystic Growth in Early Infancy

Hiromi Mori<sup>2</sup>, Nao Uchida<sup>1</sup>, Yurika Uematsu<sup>1</sup>, Miyu Sai<sup>1</sup>, Takuto Miura<sup>1,3</sup>,  
Toshinari Takahashi<sup>1,4</sup>, Tetsushi Inagaki<sup>2</sup>, Atsuo Kikuchi<sup>1</sup>

<sup>1</sup>Department of Pediatrics, Tohoku University Hospital, <sup>2</sup>Department of Nephrology, Miyagi Children's Hospital,  
<sup>3</sup>Department of Pediatrics, Tome City Hospital, <sup>4</sup>Tsukidate Children's Clinic

**Backgrounds:** The TSC2 gene, responsible for tuberous sclerosis (TS), is located adjacent to the PKD1 gene, the causative gene for autosomal dominant polycystic kidney disease (ADPKD), on the short arm of chromosome 16. Consequently, a deletion spanning both genes results in TSC2-PKD1 contiguous gene syndrome (PKD-TS). Patients with PKD-TS typically develop numerous bilateral renal cysts starting in early infancy and often progress to renal failure at a much younger age than those with typical ADPKD.

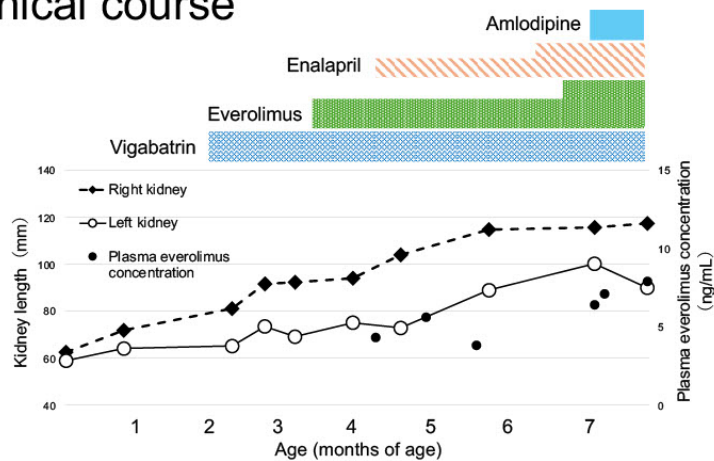
**Case:** The patient is a 7-month-old girl with no family history of TS or ADPKD. Fetal ultrasonography suggested cardiac rhabdomyoma, leading to manage pregnancy. She was born at 40 weeks of gestation (birth weight: 3,013 g) without asphyxia. While the cardiac tumors regressed spontaneously, brain MRI revealed multiple nodules, and abdominal ultrasonography showed bilateral multiple renal cysts. Chromosomal microarray analysis detected a short deletion at 16p13.3 involving both TSC2 and PKD1, confirming a diagnosis of PKD-TS. At 2 months of age, she developed West syndrome and was referred to our department for management of TS and polycystic kidney disease. At the initial visit, renal length was 81.1 mm (right) and 65.1 mm (left). Over the subsequent 1.5 months, the kidneys rapidly enlarged to 94.0 mm (right) and 72.0 mm (left). Following discussions with the neurology team and the parents, the mTOR inhibitor everolimus was initiated 3 months of age. As of 7 months of age, the kidneys have continued to enlarge (right: 115.7 mm, left: 95.0 mm), though renal function remains within the normal range.

**Conclusions:** PKD-TS often progresses to end-stage renal disease (ESRD) during the second or third decade of life. Although a few cases have reported that mTOR inhibitors or tolvaptan suppressed cyst growth, clinical evidence remains insufficient. In this case, given the rapid cystic enlargement during early infancy, everolimus was started at 3 months of age with the hope of slowing disease progression. Moving forward, we will continue to evaluate the efficacy of everolimus and consider the administration of tolvaptan once the patient is able to maintain autonomous fluid intake.

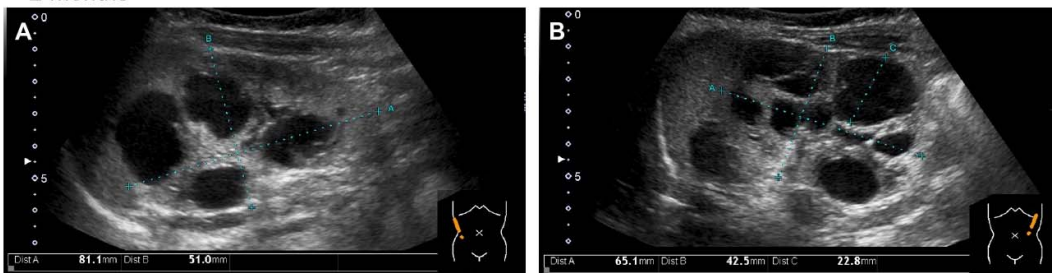
**Points of discussion:** Evidence for the efficacy of mTOR inhibitors and tolvaptan in this condition is currently limited to sporadic case reports. In our patient, we plan to temporarily discontinue the mTOR inhibitor for approximately six months at age one for live vaccinations, which may allow us to assess the treatment's effectiveness. We invite comments from clinicians who have managed similar cases and can share their longitudinal outcomes.

**Keywords:** ADPKD, tuberous sclerosis complex, TSC2/PKD1 contiguous gene syndrome, everolimus

### Clinical course



<2 months>



<7 months>

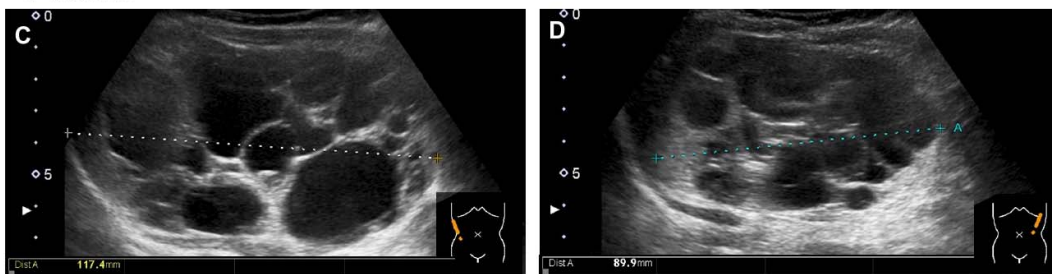


Figure. Ultrasonographic image of kidney A) B) at two months of age , C) D) at seven months of age



## Deep Intronic IFT172 Variants Causing Cryptic Exon Activation Identified by Whole Genome Sequencing in Nephropathy

**Shuhei Aoyama<sup>1</sup>, China Nagano<sup>1</sup>, Asahi Yamamoto<sup>1,2</sup>, Yuka Kimura<sup>1</sup>, Yuta Inoki<sup>1</sup>,  
Nana Sakakibara<sup>1</sup>, Tomoko Horinouchi<sup>1</sup>, Tomohiko Yamamura<sup>1</sup>, Shingo Ishimori<sup>1</sup>,  
Naoya Morisada<sup>3</sup>, Kandai Nozu<sup>1</sup>**

<sup>1</sup>Department of Pediatrics, Kobe University Graduate School of Medicine, Kobe, Japan, <sup>2</sup>Department of Pediatrics, Hokkaido University Graduate School of Medicine, Sapporo, Japan, <sup>3</sup>Department of Clinical Genetics, Hyogo Prefectural Children's Hospital, Kobe, Japan

**Backgrounds:** IFT172 is one of the causative genes of ciliopathies, a group of disorders frequently involving the kidney. Although pathogenic coding variants have been well described, the contribution of deep intronic variants remains underrecognized in nephropathy and is often missed by conventional genetic testing. We report two patients with nephropathy in whom whole genome sequencing identified deep intronic IFT172 variants predicted to cause aberrant splicing following non-diagnostic results from targeted exome sequencing.

**Case:** In Case 1, a 13-year-old boy with nephronophthisis, kidney dysfunction (eGFR 18ml/min/1.73m<sup>2</sup>) and no extrarenal manifestations, segregation analysis confirmed that a deep intronic variant and a missense variant were present in trans, and SpliceAI predicted cryptic exon activation caused by the deep intronic variant, resulting in a premature termination codon. In Case 2, a 23-year-old man with adolescent-onset kidney dysfunction (eGFR 64ml/min/1.73m<sup>2</sup>) and no extrarenal manifestations, a deep intronic IFT172 variant was detected together with a missense variant; the phase of these variants is currently under investigation. SpliceAI consistently predicted cryptic exon inclusion leading to a premature termination codon, and a minigene assay demonstrated aberrant splicing consistent with the same pseudoexon activation.

**Conclusions:** These cases demonstrate that deep intronic IFT172 variants can cause pathogenic splicing abnormalities and highlight the diagnostic value of whole genome sequencing following non-diagnostic targeted exome analysis. Splice-aware interpretation of non-coding variants using SpliceAI is essential for achieving an accurate molecular diagnosis in nephropathy.

### Points of discussion:

1. When should whole genome sequencing be considered in patients with suspected genetic nephropathy after non-diagnostic results from targeted exome sequencing?
2. Diagnostic strategies for genetic nephropathy across different genetic testing environments in East Asia.

**Keywords:** ciliopathy, IFT172, whole genome sequencing

P1-7

## Genetic Diagnosis of Pediatric Autosomal Dominant Polycystic Kidney Disease: A Retrospective Review at Our Center

Wataru Shimabukuro<sup>1</sup>, Tomoki Akamine<sup>1</sup>, Shogo Nakada<sup>1</sup>, Kazuya Hamada<sup>1</sup>, Noriko Kinjo<sup>1</sup>, Yu Tanaka<sup>2</sup>, Naoya Morisada<sup>3,4</sup>, Kandai Nozu<sup>4</sup>, Koichi Nakanishi<sup>1</sup>

<sup>1</sup>Department of Child Health and Welfare (Pediatrics), Graduate School of Medicine, University of the Ryukyus, Nishihara, Okinawa, Japan, <sup>2</sup>Department of Nephrology, Hyogo Prefectural Kobe Children's Hospital, Kobe, Hyogo, Japan, <sup>3</sup>Department of Clinical Genetics, Hyogo Prefectural Kobe Children's Hospital, Kobe, Hyogo, Japan, <sup>4</sup>Department of Pediatrics, Kobe University Graduate School of Medicine, Kobe, Hyogo, Japan

**Backgrounds:** In adult patients clinically diagnosed with autosomal dominant polycystic kidney disease (ADPKD), genetic variants in PKD1 or PKD2 are identified in approximately 90% of cases by genetic testing.

**Case: Purpose / Methods:** We retrospectively reviewed eight pediatric patients clinically diagnosed with ADPKD who visited our department since 2017. Clinical features, genetic testing results, and the variant detection rate were evaluated based on medical records.

**Results:** The median age at diagnosis was 9.4 (range: 3.4–14.3) years. Initial presentations included abdominal pain (n=4), gross hematuria (n=3), and detection by fetal ultrasonography (n=1). At the final follow-up, the median age and estimated glomerular filtration rate were 14.1 (range: 10.9–17.9) years and 96.6 (range: 74.3–145.5) mL/min/1.73 m<sup>2</sup>, respectively. Two patients were receiving antihypertensive medication for hypertension, and no cerebral aneurysms were detected in the two patients who underwent brain MRI. A family history was present in four cases. Among the four patients without a family history, genetic testing (a panel analysis for CAKUT/CKD-related diseases) identified a pathogenic variant in only one (PKD1).

**Conclusions:** In our cohort of pediatric ADPKD patients without a family history, the detection rate of pathogenic variants was low (25%). To further investigate the underlying genetic etiology, whole-genome sequencing is currently being performed in two of the three cases where no variants were initially identified.

**Points of discussion:**

Is the variant detection rate in pediatric ADPKD lower than that in adult cohorts?

What are the underlying reasons for the lower detection rate in pediatric cases?

**Keywords:** ADPKD; children; genetic testing



P1-8

## Hepatorenal Ciliopathy Mimicking Autosomal Recessive Polycystic Kidney Disease in Childhood

Hee Sun Baek, Min Ji Park, Min Hyun Cho

Department of Pediatrics, Kyungpook National University, School of Medicine, Daegu, Republic of Korea

**Backgrounds:** Hepatorenal fibrocystic diseases (HRFCDs) are a group of prototypic ciliopathies caused by structural and functional defects of primary cilia, leading to fibrocystic involvement of the kidney and liver, with ARPKD and TMEM67 related Joubert/COACH or NPHP associated CHF representing key entities in the pediatric spectrum. These hepatorenal ciliopathies can result in severe complications, including kidney failure and portal hypertension, making clinicogenetic classification that integrates imaging, histology, and molecular diagnostics essential for prognosis and for planning transplantation and long term follow up. Here, we present a case of a child under follow-up with suspected ARPKD who was diagnosed with another disease through genetic testing.

**Case:** A 12-year-old girl was referred to our tertiary center for postnatal evaluation of abnormal renal echogenicity detected on prenatal ultrasonography. There was no family history of renal disease, and no perinatal respiratory distress was noted. Initial renal ultrasonography demonstrated mildly enlarged kidneys with diffusely increased echogenicity and several tiny cysts localized to the renal pyramids. Hepatobiliary ultrasonography revealed a slightly decreased caliber of the common bile duct, raising suspicion for autosomal recessive polycystic kidney disease (ARPKD). At approximately 3 months of age, she presented with seizure-like movements, but electroencephalography and brain MRI showed no abnormal findings. Ophthalmologic examination performed for retinal hemorrhage demonstrated neither coloboma nor cataract. During follow-up, characteristic facial dysmorphism including hypertelorism and frontal bossing became evident, accompanied by mild intellectual disability. Serial laboratory studies showed progressive elevation of blood urea nitrogen and serum creatinine levels. Urinalysis revealed negative occult blood, trace proteinuria, a urine protein-to-creatinine ratio of 0.98, and markedly elevated urinary  $\beta$ 2-microglobulin 6,931 g/gCr, indicating tubular proteinuria. Whole-exome sequencing (trio) identified a pathogenic mutation in the TMEM67 gene, and the patient is currently under multidisciplinary management involving pediatric nephrology and clinical genetics teams.

**Points of discussion :**

1. What diseases and clinical differential points should be considered in children with polycystic kidney and hepatic abnormalities in infancy?
2. What is the role of comprehensive genetic testing in ARPKD like phenotypes?

**Keywords:** Hepatorenal Ciliopathy, Autosomal Recessive Polycystic Kidney Diseases



P2-1

## Severe Early-Onset Cystic Kidney Disease Associated with a De Novo Heterozygous NEK8 Variant: An ARPKD-Mimicking Phenotype

Hyuna Lee<sup>1</sup>, Jeesu Min<sup>2</sup>, Naye Choi<sup>3,4</sup>, Jung Sue Kim<sup>5</sup>, Ji Hyun Kim<sup>4,6</sup>,  
Hee Gyung Kang<sup>3,4</sup>, Yo Han Ahn<sup>3,4</sup>

<sup>1</sup>Department of Pediatrics, Ajou University Hospital, Suwon, Korea, <sup>2</sup>Department of Pediatric, Chungnam National University Sejong Hospital, Sejong, Korea, <sup>3</sup>Department of Pediatric, Seoul National University Children's Hospital, Seoul, Korea, <sup>4</sup>Department of Pediatric, Seoul National University College of Medicine, Seoul, Korea, <sup>5</sup>Department of Pediatric, Cheongju St.Mary's Hospital, Cheongju, Korea, <sup>6</sup>Department of Pediatric, Seoul National University Bundang Hospital, Seongnam-si, Korea

**Backgrounds:** Polycystic kidney disease (PKD) in children is a rare genetic disease characterized by numerous fluid-filled cysts in the kidneys, leading to progressive loss of kidney function. Infants with autosomal recessive PKD (ARPKD), often present with complications such as pulmonary hypoplasia due to oligohydramnios, large flank masses, hematuria, or hypertension. Additionally, hepatic fibrosis and/or liver cysts may develop, potentially progressing to portal hypertension. Excessively large cystic kidneys can hinder growth and development. Here, we present a patient with de novo heterozygous NEK8 variant who experienced multiple severe complications.

**Case:** A 33-month-old boy with a de novo heterozygous NEK8 variant is undergoing peritoneal dialysis. He was born at 36+4 weeks of gestational age, weighing 3.25kg, and was admitted to neonatal intensive care unit for respiratory failure due to prenatal pulmonary hypoplasia and oligohydramnios. After admission due to acute respiratory failure at 7 months of age (height of 65cm, <3 percentile and weight of 11.1kg, >97 percentile), his kidney function had been decreased requiring kidney replacement therapy. To create space for peritoneal dialysis, a unilateral nephrectomy was performed as his abdominal cavity was occupied by polycystic kidneys. The resected kidney weighed 1.758kg, nearly nine times the weight of a normal adult kidney. During temporary hemodialysis after inserting peritoneal catheter, he suffered esophageal bleeding and recurrent severe hypotension. He was suffered from severe urinary tract infections in the remaining kidney, which required hospitalization for septic shock and antibiotics-resistant bacterial infections. Following contralateral nephrectomy, remained clinically stable with adequate dialysis clearance. Subsequent genetic testing identified a heterozygous de novo variant in NEK8 (NM\_178170.3:c.626C>T, p.Pro209Leu). This molecular finding prompted re-

consideration of the initial clinical diagnosis of autosomal recessive polycystic kidney disease, suggesting a ciliopathy-related nephronophthisis spectrum disorder associated with NEK8 dysfunction.

**Conclusion:** Although pathogenic biallelic variants in NEK8 are an established cause of severe nephronophthisis-spectrum ciliopathy with ARPKD-like features, the pathogenic role of a single heterozygous NEK8 variant remains unclear. Our case raises the possibility that monoallelic NEK8 variants may contribute to severe infantile cystic kidney disease, potentially through dominant-negative effects, undetected second hits, or modifier genes.

**Point of discussion:** Can a single heterozygous de novo NEK8 variant sufficiently explain a severe ARPKD-like phenotype, and should NEK8-related ciliopathy be considered in the differential diagnosis of infants clinically diagnosed with ARPKD but lacking classical biallelic pathogenic variants?



## Genotype–phenotype analysis of renal tubular dysgenesis caused by angiotensinogen variants

Yuka Kimura<sup>1</sup>, China Nagano<sup>1</sup>, Koichi Kamei<sup>2</sup>, Kentaro Nishi<sup>2</sup>, Kano Yuji<sup>3</sup>, Hiroshi Suzumura<sup>3</sup>, Asahi Yamamoto<sup>1</sup>, Shuhei Aoyama<sup>1</sup>, Yuta Inoki<sup>1</sup>, Nana Sakakibara<sup>1</sup>, Tomoko Horinouchi<sup>1</sup>, Tomohiko Yamamura<sup>1</sup>, Shingo Ishimori<sup>1</sup>, Naoya Morisada<sup>4</sup>, Kandai Nozu<sup>1</sup>

<sup>1</sup>Department of Pediatrics, Kobe University Graduate School of Medicine, Kobe, Japan, <sup>2</sup>Division of Nephrology and Rheumatology, National Center for Child Health and Development, Tokyo, Japan, <sup>3</sup>Department of Pediatrics, Dokkyo Medical University, Tochigi, Japan, <sup>4</sup>Department of Clinical Genetics, Hyogo Prefectural Kobe Children's Hospital, Kobe, Japan

**Backgrounds:** Renal tubular dysgenesis (RTD) caused by angiotensinogen (AGT) variants is a rare and often lethal disorder resulting from defects in the renin–angiotensin system. Truncating variants are generally presumed to result in more severe phenotypes than non-truncating variants due to complete loss of protein function. However, genotype–phenotype correlations and treatment effects remain incompletely understood.

**Case:** We analyzed 24 patients with genetically confirmed RTD caused by AGT variants, including previously reported cases. 14 patients had biallelic truncating variants, 9 had biallelic non-truncating variants, and 1 had compound heterozygous variants consisting of truncating and non-truncating variant. Perinatal lethality occurred in 64% of patients with truncating variants and 56% of those with non-truncating variants, with no significant association between genotype and lethality. Kaplan–Meier survival analysis also demonstrated no significant difference between genotype groups (log-rank  $p=0.81$ ). Fresh frozen plasma (FFP) therapy was administered in 6 patients with truncating variants. Survival was more frequently observed in patients who received FFP than in those who did not, although treatment exposure was imbalanced between genotype groups. Among surviving patients ( $n=7$ ), the median follow-up duration was 4 years (range, 10 months–20 years). 4 patients required acute peritoneal dialysis during the neonatal period, 3 of whom were able to discontinue dialysis. At the last follow-up, only 1 patient required ongoing chronic renal replacement therapy.

**Conclusions:** No clear genotype–phenotype correlation was observed in RTD caused by AGT variants. However, FFP therapy was associated with improved survival in some patients, suggesting a potential therapeutic benefit.

**Points of discussion:** These findings suggest that variant type alone may not determine clinical outcome in RTD caused by AGT variants. Both truncating and non-truncating variants may result in severe functional



impairment. In addition, therapeutic interventions such as FFP may modify disease course and improve survival. Early diagnosis and timely treatment may be important for improving outcomes in this condition.

**Keywords:** Renal tubular dysgenesis, angiotensinogen, fresh frozen plasma therapy



## RNF213-Associated Vasculopathy with Renal and Pulmonary Artery Stenosis in a Child with Moyamoya Disease

Jun Sada<sup>1</sup>, Chikako Terano<sup>1,2</sup>, Mayuko Terasawa<sup>1</sup>, Ryo Masaoka<sup>1</sup>, Masatoshi Yoshikane<sup>1</sup>, Hisaki Kawamukai<sup>1</sup>, Kazuki Tanaka<sup>1</sup>, Naoya Fujita<sup>1</sup>

<sup>1</sup>Department of Nephrology, Aichi Children's Health and Medical Center, Aichi, Japan, <sup>2</sup>Department of Pediatrics, Kitasato University School of Medicine, Kanagawa, Japan

**Backgrounds:** RNF213 is a susceptibility gene for moyamoya disease (MMD) and has recently been implicated in a systemic stenosing vasculopathy affecting multiple vascular beds. Renal artery stenosis causing renovascular hypertension (RVH) can be a key manifestation of RNF213-associated vasculopathy.

**Case:** A 7-year-old Japanese girl developed severe hypertension during follow-up after revascularization surgery for MMD, which had been diagnosed at age 3. At age 5, contrast-enhanced CT revealed proximal left renal artery stenosis with thoracoabdominal aortic wall thickening, and renovascular hypertension (RVH) was diagnosed. Renal function was initially preserved (Cr 0.23 mg/dL) and triple antihypertensive therapy (amlodipine, candesartan, and bisoprolol) was initiated and up-titrated. She was referred to our center at age 6. Her blood pressure remained elevated at 127/71 mmHg (systolic >99th percentile and diastolic approximately 93rd percentile), with impaired renal function (Cr 0.53 mg/dL; Cr-eGFR 77.3 mL/min/1.73 m<sup>2</sup>). DMSA renal scintigraphy showed markedly reduced left renal function (split renal function: right 82%, left 18%). Selective renal angiography confirmed proximal left renal artery stenosis and pulmonary angiography demonstrated diffuse peripheral pulmonary artery stenosis with mild pulmonary hypertension. Inflammatory markers and autoantibodies were negative. Gene panel testing identified a novel heterozygous RNF213 variant (c.12350T>C; p.Leu4117Pro), classified as a variant of uncertain significance; given the characteristic multisite stenoses, she was considered clinically consistent with RNF213-associated vasculopathy. Her blood pressure is currently controlled and renal function remains stable on antihypertensive therapy. Percutaneous transluminal renal angioplasty will be considered if hypertension becomes medically refractory or organ dysfunction progresses. Given previous reports of restenosis and procedural complications in RNF213-associated vasculopathy, we prioritized careful medical management over immediate revascularization.

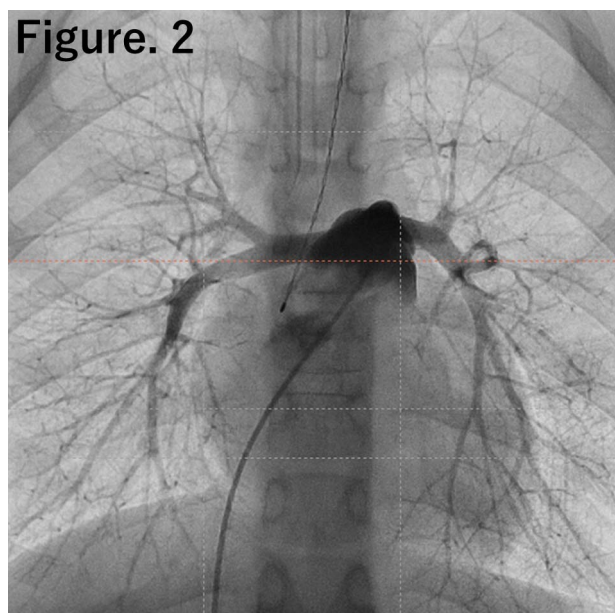
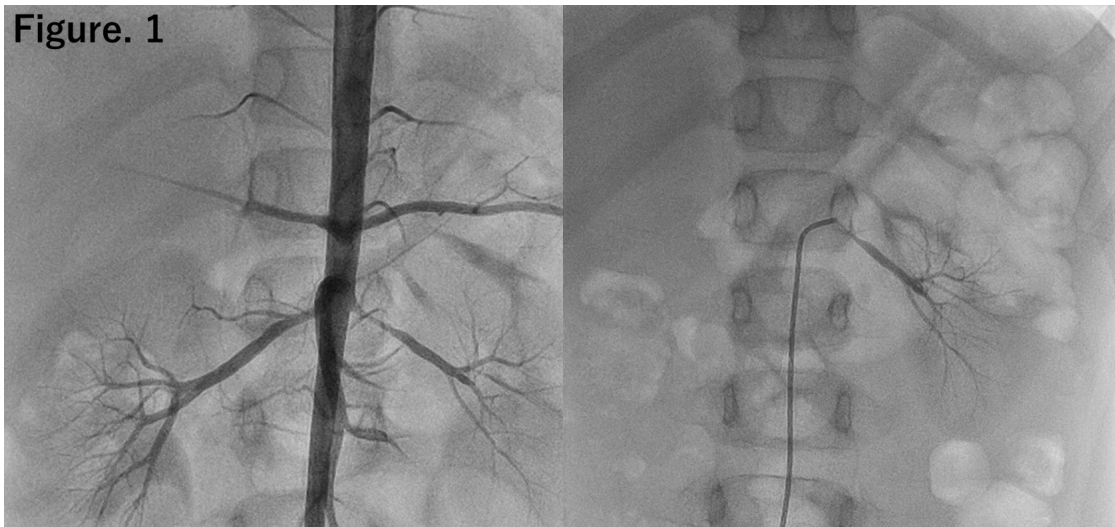
**Conclusions:** When children with MMD develop RVH or extracranial arterial stenosis, an underlying genetic vasculopathy should be suspected. Even variants of uncertain significance may be clinically relevant when ac-

accompanied by characteristic systemic vascular involvement, and careful long-term vascular surveillance is essential.

**Points of discussion :**

- Should renal revascularization be performed early in suspected RNF213-associated vasculopathy, despite potential procedural risks?
- What is the optimal imaging modality and surveillance interval for progressive systemic stenosis in children with RNF213 variants?

**Keywords:** renovascular hypertension; RNF213 variant; RNF213-associated vascular disease; moyamoya disease





## Genetic Variants in Pediatric Renovascular Hypertension: A Single-Center Study

Jeong Yeon Kim, Heeyeon Cho

Department of Pediatrics, Samsung Medical Center, Sungkyunkwan University School of Medicine, Seoul, South Korea

**Background:** Pediatric renovascular hypertension (RVH) differs significantly from adult forms, often arising from underlying vascular anomalies or monogenic syndromes rather than atherosclerosis. Identifying the specific etiology of renal artery stenosis is essential for guiding optimal management plans—such as selecting between revascularization and medical therapy—and for improving long-term clinical outcomes. Therefore, we aimed to investigate the genetic landscape of pediatric RVH in a single-center cohort

**Methods & Material:** We conducted a retrospective review of pediatric patients (aged 0–18 years) diagnosed with RVH and managed at Samsung Medical Center over a 10-year period between 2016 and 2025. We analyzed demographic data, clinical features, and genetic test results. Genetic testing strategies included targeted Sanger sequencing, whole exome sequencing (WES), or whole genome sequencing (WGS). The specific testing modality was selected based on clinical judgment, phenotypic presentation, and the availability of tests at the time of diagnosis.

**Result:** A total of 58 pediatric patients with RVH were managed during the study period. Genetic testing was performed in 40 patients, of whom 60% were female. The spectrum of underlying etiologies was diverse: moyamoya disease (MMD, 25%) and vasculopathy of unknown origin (25%) were the most common, followed by RNF213-related vasculopathy without MMD (15%). Less frequent causes included Takayasu arteritis (7.5%), fibromuscular dysplasia (5%), Klippel-Trenaunay-Weber syndrome (2.5%), ROHHAD syndrome (2.5%), and others (17.5%). Targeted evaluation of the RNF213 c.14429G>A variant in 37 patients identified 5 heterozygous and 9 homozygous cases. Additionally, broad screening via WES (n=10) and WGS (n=1) was performed, identifying diagnostic variants in 2 patients via WES, including pathogenic mutations in ANO1 and a distinct RNF213 variant (c.14749G>A).

**Conclusion:** RNF213 variants are a predominant cause of pediatric RVH in this Korean pediatric cohort, manifesting as either MMD with renal artery stenosis or isolated vasculopathy. The identification of additional var-

iants via WES underscores the clinical utility of broad genetic screening. With the increasing accessibility of NGS, systematic genetic evaluation should be integrated into standard diagnostic workups to elucidate etiology and guide long-term management.

### Point of Discussion

1. When should we use targeted RNF213 (e.g., c.14429G>A) versus a broader approach (WES, or WGS), and what clinical/imaging features should trigger escalation?
2. How should we manage the “unsolved” cases—patients without genetic testing and those with negative WES/WGS results?



P2-5

## Clinical features and genetic variations in 5 children with Schimke immunoskeletal dysplasia

Qian Li, Shuzhen Sun, Suwen Liu, Lichun Yu, Jing Wang, Zhenle Yang,  
Cong Wang, Xiaoyuan Wang

Department of Pediatric Nephrology and Rheumatism and Immunology, Shandong Provincial Hospital Affiliated to Shandong First Medical University, Jinan 250021, P. R. China

**Backgrounds:** The clinical features of Schimke immunoskeletal dysplasia (SIOD) primarily include short stature due to vertebral epiphyseal dysplasia, T-cell immunodeficiency, and progressively worsening renal impairment.

**Case:** Objective To summarize the clinical features and SMARCAL1 gene mutation in 5 children with SIOD. Methods The clinical data of 5 children with SIOD who were treated in our hospital from 2017 to 2026 were retrospectively analyzed.

**Results:** Among the 5 pediatric patients (4 males and 1 female), the age of onset ranged from 1.5 to 8 years, with all presenting with short stature and epiphyseal dysplasia. Four cases exhibited nephrotic syndrome manifestations, and one case with mild proteinuria, one with a duplicated kidney with malrotation in the right kidney. Renal biopsy revealed focal segmental glomerulosclerosis with tubulointerstitial inflammation in one case. Three cases had recurrent infections, while three patients showed neutropenia and lymphopenia. Two cases presented with hearing loss and secretory otitis media, one with amblyopia, and one with concurrent atrial septal defect. Genetic testing confirmed SMARCAL1 gene abnormalities in all cases. During 1~4.5 years of follow-up, one patient maintained normal renal function, while the other four progressed to stage 5 chronic kidney disease (CKD).

**Conclusions:** The clinical symptoms of SIOD are varied and the disease progresses at different degrees. The treatment is mainly symptomatic and the prognosis is poor.

### Points of discussion :

What is the differential diagnosis?

**Keywords:** Schimke immunoskeletal dysplasia, genotype, phenotype, child

P2-6

## An Infant girl with Frasier syndrome detected through the kindergarten urinalysis screening test

Masayuki Ishihara<sup>1</sup>, Yoshiki Nagao<sup>1</sup>, Haruki Mishima<sup>1</sup>, Yuta Inoki<sup>2</sup>, Nana Sakakibara<sup>2</sup>,  
China Nagano<sup>2</sup>, Kandai Nozu<sup>2</sup>, Mariko Taniguchi-Ikeda<sup>1</sup>

<sup>1</sup>Department of Pediatrics, Kochi Medical School, Kochi University,

<sup>2</sup>Department of Pediatrics, Kobe University Graduate School of Medicine

**Backgrounds:** Frasier syndrome is a rare WT1-related disorder characterized by progressive nephropathy and 46,XY disorder of sex development. It typically presents with asymptomatic proteinuria between 2 and 6 years of age and often progresses to end-stage kidney disease during adolescence.

**Case:** An 11-month-old girl with no significant family history was referred to our hospital. She was born at 38 weeks of gestation (birth weight 3,198 g; length 50.5 cm) without perinatal asphyxia. External genitalia were normal female, and her development was age-appropriate. Proteinuria was detected during routine kindergarten screening several months after enrollment. She was diagnosed with nephrotic syndrome and treated with corticosteroids. However, she failed to achieve complete remission after 4 weeks of treatment and underwent renal biopsy. Pathology revealed focal segmental glomerulosclerosis-like changes with swelling, vacuolation, and cystic changes of the proximal tubules. Immunofluorescence showed weak IgM positivity.

Three courses of methylprednisolone pulse therapy were ineffective, and cyclosporine was initiated, resulting in improvement of proteinuria and hypoalbuminemia.

Genetic testing identified a WT1 splice-site variant, c.1447+5G>A (IVS9+5G>A), predicted to cause abnormal splicing. Karyotype was 46,XX.

**Conclusions:** This case highlights that Frasier syndrome, typically associated with 46,XY disorder of sex development, can also occur in patients with a 46,XX karyotype, underscoring the importance of genetic evaluation in steroid-resistant nephrotic syndrome.

### Points of discussion:

- What is the optimal use of calcineurin inhibitors to preserve renal function?
- How should nephrotic syndrome be managed when systemic edema worsens?
- What are the clinical implications of a 46,XX karyotype in Frasier syndrome?

**Keywords:** Frasier syndrome, steroid-resistant nephrotic syndrome, WT-1 related disorder



P2-7

## A Case of Frasier Syndrome with Hereditary FSGS Responsive to Cyclosporine

Shingo Niimi<sup>1</sup>, Yusuke Hiyoshi<sup>1</sup>, Satoko Kurata<sup>1</sup>, Kandai Nozu<sup>2</sup>, Seiji Tanaka<sup>1</sup>

<sup>1</sup>Department of Pediatrics, Kurume University School of Medicine, Japan,  
<sup>2</sup>Department of Pediatrics, Kobe University Graduate School of Medicine, Japan

**Backgrounds:** Focal segmental glomerulosclerosis (FSGS) is classified into primary, secondary, and genetic forms. Genetic FSGS is caused by mutations in podocyte-related genes, such as WT1, and is generally resistant to steroids and other immunosuppressive agents. Frasier syndrome, caused by WT1 gene mutations, is characterized by progressive nephropathy in addition to disorders of sex development and gonadal tumors. We report a case of Frasier syndrome with hereditary FSGS that responded to cyclosporine.

**Case:** A 4-year-old girl was noted to have 2+ proteinuria on routine urinalysis at 3 years of age and was referred to a local physician. Urinalysis revealed 3+ proteinuria, and the urine protein-to-creatinine ratio was 10.25 g/gCr. She was subsequently referred to our hospital. The urine protein-to-creatinine ratio ranged from 7–10 g/gCr, and serum albumin was 3.0 g/dL, indicating persistent heavy proteinuria. Renal biopsy was performed and led to a diagnosis of FSGS.

She received three courses of methylprednisolone pulse therapy followed by oral prednisolone; however, she was steroid-resistant. Cyclosporine was added, resulting in a reduction of the urine protein-to-creatinine ratio to 3 g/gCr. Genetic testing subsequently confirmed a diagnosis of Frasier syndrome. Prednisolone was gradually tapered and discontinued, and cyclosporine monotherapy was continued.

The urine protein-to-creatinine ratio remained around 3 g/gCr, and cyclosporine was therefore tapered due to presumed lack of efficacy. However, proteinuria worsened to 7 g/gCr, prompting re-escalation of cyclosporine. Currently, the urine protein-to-creatinine ratio is maintained at approximately 2 g/gCr.

**Conclusions:** WT1-associated nephropathy, including that observed in Frasier syndrome, is regarded as a podocyte disorder. Calcineurin inhibitors, including cyclosporine, are thought to stabilize the podocyte actin cytoskeleton and may thus represent a potential therapeutic option for WT1-associated nephropathy.

**Points of discussion:** The impact of calcineurin inhibitors on long-term renal prognosis in WT1-associated nephropathy remains uncertain, and further accumulation of clinical cases is needed.

**Keywords:** Frasier Syndrome, FSGS, Cyclosporine

P2-8

## Infantile-onset X-linked Alport syndrome with predominant tubulointerstitial fibrosis and impaired tubular organization in patient-derived kidney organoids

Panpan Shao, Yonghua He, Liru Qiu

Department of Pediatrics, Tongji Hospital, Tongji Medical College, Huazhong University of Science and Technology, Wuhan, PR China 430030

**Backgrounds:** Alport syndrome (AS) is a hereditary nephropathy caused by pathogenic variants in type IV collagen genes, classically viewed as a glomerular basement membrane (GBM) disorder leading to hematuria, proteinuria, and progressive renal failure. However, mechanisms underlying very early-onset AS and disproportionate tubulointerstitial injury remain poorly understood. Here, we report an infantile-onset, rapidly progressive X-linked AS case with prominent tubulointerstitial fibrosis and investigate intrinsic developmental abnormalities using a patient-derived iPSC kidney organoid model.

**Case:** A male infant conceived via in vitro fertilization was suspected of having congenital nephrotic syndrome in early life. He developed eyelid edema in infancy with nephrotic-range proteinuria and persistent hematuria. Complement levels were decreased during evaluation (C3 0.64 g/L, C4 0.15 g/L), which initially complicated the differential diagnosis. Despite immunosuppressive therapy (corticosteroids and tacrolimus), renal function deteriorated rapidly, and the patient eventually required intermittent peritoneal dialysis. Renal biopsy showed dominant tubulointerstitial injury with marked tubular atrophy/interstitial fibrosis, while electron microscopy revealed irregular GBM thickening with lamellation and splitting, consistent with AS. Trio whole-genome sequencing identified a hemizygous pathogenic nonsense variant in COL4A5 (NM\_033380.3:c.4357C>T, p.Gln1453\*), confirmed by Sanger sequencing and absent in both parents, suggesting a de novo event. Patient-derived iPSC kidney organoids demonstrated abnormal embryoid body formation with loose cell aggregation and reduced compaction. During differentiation, organoids showed weaker expression of LTL and CDH1 compared with controls. In a 2D dual-layer Matrigel differentiation assay, patient organoids displayed scattered LTL expression rather than continuous tubular structures, indicating impaired tubular differentiation and organization.

**Conclusions:** This case represents severe infantile-onset X-linked AS due to a de novo COL4A5 truncating variant, characterized clinically by rapid progression and pathologically by prominent tubulointerstitial fibrosis in



addition to typical GBM changes. Patient-derived kidney organoids showed intrinsic defects in nephron/tubular structural organization, supporting the hypothesis that COL4A5 dysfunction may contribute to renal tubular developmental instability and accelerate progression in early-onset disease.

**Points of discussion:**

1. Early-onset AS can clinically mimic congenital/infantile nephrotic syndrome and may be misdirected toward immunosuppression; early genetic testing should be prioritized in steroid-resistant cases.
2. The disproportionate tubulointerstitial fibrosis suggests that tubulointerstitial pathology may be primary rather than purely secondary to glomerular injury.
3. The organoid phenotype (abnormal EB compaction, reduced LTL/CDH1, disrupted tubular continuity) provides experimental evidence for a developmental component in AS and motivates staged molecular profiling (e.g., qPCR across differentiation stages and pathway interrogation) to define mechanisms and optimize differentiation conditions.

**Keywords:** Alport syndrome, COL4A5, Tubulointerstitial fibrosis, Kidney organoids

P2-9

## A Case of Male Infantile Neuroblastoma Who Developed Refractory Hypertension Due to Excessive Catecholamine after Aparotomy Biopsy

**Ryouta Agune, Seiji Tanaka, Shingo Niimi, Keishirou Houjou, Yuusuke Hiyoshi, Junpei Mukai, Shuichi Ozono, Ryuta Nishikomori**

Department of Pediatrics and Child Health, Kurume University

**Backgrounds:** Despite being a catecholamine-producing tumor, neuroblastoma rarely presents with hypertension, occurring in only about 0.2% of cases, because it does not exhibit catecholamine excess symptoms. This is thought to be due to immature endoplasmic reticulum formation and issues with dopamine metabolites.

**Case:** 1- month-old male infant: Abdominal distension was noted at the 14day checkup, followed by poor feeding and decreased bowel movements. Ultrasound and contrast-enhanced CT confirmed a left renal mass. Elevated tumor markers were detected in the blood. Aldosterone and renin activity were also elevated. An open biopsy led to a diagnosis of neuroblastoma. During the open biopsy, blood pressure reached 170 mmHg. Postoperatively, systolic blood pressure remained persistently elevated at 120-140 mmHg or higher. Various antihypertensive agents were used, but control proved difficult. Ultimately, a beta-blocker (doxazosin) stabilized the blood pressure. Following chemotherapy, the tumor shrank, norepinephrine and dopamine levels decreased, and sweating and weight loss improved. Tumor markers, renin, and aldosterone also decreased. However, hypertension persisted. Switching from enalapril to olmesartan improved blood pressure.

**Conclusions:** Neuroblastoma may present with hypertension, so caution is warranted. In such cases, doxazosin should be actively considered as the antihypertensive agent of choice.

**Points of discussion:** I would like to hear your opinion regarding blood pressure management.

**Keywords:** Neuroblastoma, hypertension, doxazosin



P3-1

## Compound Heterozygous RRM2B Mutations Associated with Nephrotic Syndrome and Multiple Systemic Abnormalities in a Pediatric Patient

Lei Sun, Xin-yu Kuang, Wen-yan Huang, Yu-lin Kang

Department of Nephrology and Rheumatology, Shanghai Children's Hospital, School of Medicine, Shanghai Jiaotong University, Shanghai, 200062, China

**Backgrounds:** The RRM2B gene encodes the small subunit of p53-induced ribonucleotide reductase, playing a pivotal role in DNA synthesis, repair, and cell cycle progression. Accumulating evidence indicates that pathogenic RRM2B mutations can cause multiple systemic abnormalities (renal dysfunction, auditory impairment, growth retardation) and are associated with hereditary disorders. Nephrotic syndrome is a common pediatric glomerular disease with etiologies including genetics, immunity, and environment. However, cases caused by RRM2B mutations—especially those comorbid with profound SNHL and short stature—are clinically rare and inadequately documented.

**Case:** An 8-year-old male was admitted with bilateral hearing loss for 2 years. He passed neonatal hearing screening with normal early language development, but developed idiopathic bilateral hearing loss 2 years prior (left ear 60 dB, right ear 90 dB), managed with hearing aids. Admitted for cochlear implantation evaluation, preoperative tests revealed urinary protein (4+) and hypoalbuminemia (serum albumin: 24.50 g/L), leading to transfer to Nephrology for further management. Post-admission evaluations showed persistent urinary protein (3+~4+), elevated 24-hour urinary protein (1.74 g), elevated urinary protein-to-creatinine ratio (12.20), decreased visual acuity, and slightly increased renal echogenicity on ultrasound.

Given his auditory abnormalities, decreased visual acuity, intellectual developmental delay, and nephrotic syndrome, comprehensive genetic testing identified compound heterozygous RRM2B mutations (c.371A>G, c.1036A>G). Due to poor cooperation for renal biopsy, methylprednisolone (25 mg/d, 1.87 mg/kg) and cyclosporine A (0.3 ml q12h, 4.5 mg/kg/d) were administered with good tolerance and normal blood pressure. He was discharged with clinical improvement; 3-month follow-up showed urinary protein 3+, reduced protein-to-creatinine ratio (3.51), slightly increased serum albumin (31.4 g/L), and no obvious progression of visual decline.

**Conclusions:** This study confirms an 8-year-old male patient was diagnosed with nephrotic syndrome, audi-

tory abnormalities, decreased visual acuity, and intellectual developmental delay, closely linked to compound heterozygous RRM2B mutations (c.371A>G, c.1036A>G). Without renal biopsy (due to poor patient cooperation), combined methylprednisolone and cyclosporine A therapy yielded favorable outcomes, with improved urinary protein levels, serum albumin levels, and no obvious progression of visual decline on follow-up. This rare case of compound heterozygous RRM2B mutation-induced nephrotic syndrome with multiple systemic comorbidities enriches clinical data on such hereditary diseases.

**Points of discussion:**

First, this case confirms the pathogenicity of compound heterozygous RRM2B mutations (c.371A>G, c.1036A>G) in pediatric nephrotic syndrome with auditory, visual acuity, and intellectual impairments, enriching the clinical phenotype of RRM2B-related hereditary diseases and providing clinical evidence for the correlation between these mutations and multi-system damage.

Second, a limitation is the unclear pathological typing of nephrotic syndrome due to the patient's poor cooperation for renal biopsy. Renal biopsy is critical to clarify the pathological mechanism of the disease, and re-attempting it when the patient is stable and cooperative is recommended.

Third, combined methylprednisolone and cyclosporine A therapy achieved good outcomes, suggesting it may be a feasible option for such children unable to undergo renal biopsy, though long-term follow-up is needed to confirm its efficacy and safety.

**Keywords:** RRM2B; Mutation; Nephrotic Syndrome; auditory impairment



P3-2

## A rare case of steroid-sensitive nephrotic syndrome (SSNS) with podocytopathy in a child with Alport syndrome

Keum Hwa Lee<sup>1,2</sup>, Peong Gang Park<sup>1,2</sup>, Minsun Jung<sup>3</sup>, Ye Eun Ko<sup>4</sup>, Jae Il Shin<sup>1,2</sup>, Ji Hong Kim<sup>1,5</sup>

<sup>1</sup>Department of Pediatrics, Yonsei University College of Medicine, Seoul, Republic of Korea, <sup>2</sup>Division of Pediatric Nephrology, Severance Children's Hospital, Yonsei University College of Medicine, Seoul, Republic of Korea, <sup>3</sup>Department of Pathology, Yonsei University College of Medicine, Seoul, Republic of Korea, <sup>4</sup>Department of Internal Medicine, Yonsei University College of Medicine, Seoul, Republic of Korea, <sup>5</sup>Department of Pediatrics, Gangnam Severance Hospital, Seoul, Republic of Korea

**Background:** Alport syndrome is a hereditary glomerular disease caused by mutations in type IV collagen genes and is characterized by progressive hematuria, proteinuria, sensorineural hearing loss, and ocular abnormalities. However, nephrotic syndrome rarely accompanies Alport syndrome, and such presentations may lead to diagnostic and therapeutic challenges due to atypical clinical features.

**Case:** A 5-year-old boy initially presented in 2014 with generalized edema and massive proteinuria following an upper respiratory infection and was admitted through the emergency department. Clinical manifestations and laboratory findings were consistent with nephrotic syndrome. The patient showed a good response to corticosteroid therapy; however, massive proteinuria recurred upon steroid withdrawal. Based on this steroid-dependent course, minimal change disease (MCD) was suspected, and immunosuppressive therapy with cyclosporine was initiated, later switched to tacrolimus in 2020.

During long-term follow-up, persistent microscopic hematuria was noted on urinalysis. A reassessment of family history revealed glomerulonephritis in family members. With informed consent, genetic testing was performed at the age of 15 in August 2025. Genetic analysis identified compound heterozygous variants in COL4A3 (c.4793T>G, p.Leu1597Arg and c.2863G>A, p.Gly955Arg), leading to a diagnosis of autosomal recessive Alport syndrome.

All immunosuppressive agents were discontinued after the genetic diagnosis; however, the patient was re-admitted in October 2025 due to recurrent massive proteinuria with edema. A renal biopsy performed during hospitalization demonstrated histopathologic features consistent with Alport syndrome accompanied by podocytopathy. Corticosteroid and immunosuppressive therapies were reintroduced, resulting in clinical improvement, and corticosteroids were subsequently discontinued.

**Conclusion:** This case illustrates a rare presentation of Alport syndrome manifesting as steroid-responsive

nephrotic syndrome with histologic features overlapping those of MCD. In patients with nephrotic syndrome who exhibit atypical clinical courses, including persistent hematuria or a positive family history, hereditary nephropathies such as Alport syndrome should be considered. Early genetic testing combined with comprehensive clinicopathologic correlation is crucial for appropriate therapeutic decision-making and long-term prognostic management.

**Keywords:** Steroid-sensitive nephrotic syndrome (SSNS), Podocytopathy, Alport syndrome

**Points of discussion**

1. Is podocytopathy a secondary clinical manifestation of Alport syndrome, or does it represent a coincidental coexistence of two distinct diseases?
2. After identifying a pathogenic COL4A3 mutation, how should clinicians balance immunosuppressive therapy against supportive management?



## Delayed diagnosis of COQ8B nephropathy following an initial diagnosis of focal segmental glomerulosclerosis

Sakiko Oboshi<sup>1</sup>, Yuko Shima<sup>1</sup>, Hironobu Mukaiyama<sup>1</sup>, Yu Tanaka<sup>1</sup>, Tomoko Horinouchi<sup>2</sup>,  
Kandai Nozu<sup>2</sup>, Daisuke Tokuhara<sup>1</sup>, Norishige Yoshikawa<sup>3</sup>

<sup>1</sup>Pediatrics, Wakayama Medical University, <sup>2</sup>Department of Pediatrics, Kobe University Graduate School of Medicine,  
<sup>3</sup>Clinical Research Center, Takatsuki General Hospital

**Backgrounds:** COQ8B nephropathy is an autosomal recessive disorder caused by primary coenzyme Q10 (CoQ10) deficiency and is increasingly recognized as a treatable form of hereditary focal segmental glomerulosclerosis (FSGS). Although many reported cases present with steroid-resistant nephrotic syndrome or have a positive family history, the clinical spectrum is broad, and diagnosis can be challenging in patients with mild or atypical presentations.

**Case:** The patient is a 14 year old boy who was first noted to have isolated proteinuria on routine urinalysis at the age of three. From the age of five, his urine protein to creatinine ratio persistently exceeded 0.5 g/gCr, leading to a kidney biopsy at six years of age that revealed collapsing variant FSGS. He had no family history of kidney disease and no extrarenal manifestations, including hearing or ocular abnormalities. Because the biopsy showed no specific features suggestive of a secondary etiology, treatment with a renin-angiotensin system inhibitor (RASi) was initiated.

Despite RASi, proteinuria progressively worsened, becoming heavy around the age of ten and reaching nephrotic range levels by thirteen. Given the atypical course and poor response to RASi, further evaluation was performed to assess the need for steroid therapy. Serum anti nephrin antibody was negative. Genetic testing identified a known pathogenic COQ8B variant, confirming COQ8B nephropathy, and Coenzyme Q10 supplementation was subsequently initiated.

**Conclusions:** This case demonstrates that COQ8B nephropathy can initially present as isolated proteinuria without extrarenal manifestations or family history, leading to potential misclassification as primary FSGS. Although early genetic testing is crucial for accurate diagnosis and timely initiation of CoQ10 supplementation, determining the appropriate timing for such testing was challenging in this case.

**Points of discussion:** Even with a kidney biopsy, early suspicion of COQ8B nephropathy would have been difficult, and the optimal timing for genetic testing remains uncertain.

**Keywords:** COQ8 nephropathy

P3-4

## Revisiting Age-Related Declines in Urinary Protein Excretion Using Fractional Excretion of Total Protein

Shoichi Shimizu<sup>1</sup>, Shori Takahashi<sup>2</sup>, Kimitaka Nakazaki<sup>1</sup>, Tamaki Morohashi<sup>1</sup>, Ichiro Morioka<sup>1</sup>

<sup>1</sup>Department of Pediatrics and Child Health, Nihon University School of Medicine, Tokyo, Japan,  
<sup>2</sup>Itabashi Chuo Medical Center, Tokyo, Japan

**Backgrounds:** In school-aged children and adolescents, growth-associated increases in creatinine production and urinary excretion contribute to a progressive decline in the urine protein-to-creatinine ratio (UTP/Cr), a finding traditionally interpreted as reflecting a physiological reduction in urinary protein excretion. However, the UTP/Cr ratio does not account for changes in serum total protein (STP) or serum creatinine (SCr) levels, raising concerns about its validity as a quantitative measure of true protein leakage. In addition, developmental remodeling of the glomerular basement membrane during childhood involves a transition in type IV collagen composition from  $\alpha 1/\alpha 2$  to  $\alpha 3/\alpha 4/\alpha 5$  chains, a process that may alter the permeability of the glomerular filtration barrier to proteins. Therefore, we evaluated urinary protein excretion using the fractional excretion of total protein (FETP), an index that incorporates both STP and SCr.

**Case:** We analyzed data from the 2024 Tokyo Metropolitan school-based kidney screening program. Of the 418,523 children who underwent first-stage screening, 380 healthy children aged 7–15 years who completed blood and urine testing during the third-stage evaluation and were ultimately classified as having no abnormalities or asymptomatic hematuria were included. Associations between age, sex, FETP, and UTP/Cr ratio were examined using regression models with age-by-sex interaction terms. The UTP/Cr ratio declined significantly with age and demonstrated a significant age-by-sex interaction ( $p=0.033$ ). In contrast, FETP showed a distinct pattern, also demonstrating a significant age-by-sex interaction ( $p=0.002$ ) but without a comparable age-related decline.

**Conclusions:** Age-related changes in urinary protein excretion during childhood varied depending on the evaluation index used. Although the UTP/Cr ratio declined with age and may have been influenced by growth-associated increases in creatinine excretion, FETP appeared to be less affected by these changes. These findings suggest that FETP may provide a more appropriate estimate of glomerular protein leakage in growing children.



**Points of discussion:** These findings call into question the assumption that urinary protein leakage decreases with growth and suggest that the age-related decline in UTP/Cr ratio may partly reflect limitations of creatinine-based correction. In contrast, FETP may allow a more physiologically appropriate reassessment of urinary protein excretion.

**Keywords:** urine protein, fractional excretion of total protein, urine protein-to-creatinine ratio, school-based kidney screening program

P3-5

## Secukinumab in the management of generalized pustular psoriasis comorbidity with nephrotic syndrome in a young child with IL36RN variant

Weina Zhang<sup>1</sup>, Xiaohong Wu<sup>2</sup>, Min Li<sup>1</sup>, Yong Cai<sup>1</sup>, Hongrong Lin<sup>1</sup>, Huamu Chen<sup>1</sup>, Wei Han<sup>1</sup>,  
Wencheng Li<sup>3</sup>, Liangzhong Sun<sup>1</sup>

<sup>1</sup>Department of Pediatrics, Nanfang Hospital, Southern Medical University, Guangzhou 510515, China, <sup>2</sup>Department of Pediatrics, People's Hospital Of Shantou, Shantou 515011, China, <sup>3</sup>Department of Pediatric Nephrology, Guangdong Women and Children Hospital, Guangzhou 511442, China

**Backgrounds:** Generalized pustular psoriasis (GPP) is a rare, life-threatening neutrophilic dermatosis often associated with systemic comorbidities, suggesting shared immune disorders. We report a young child with GPP and idiopathic nephrotic syndrome (INS) harboring a homozygous IL36RN variant, and summarize the clinical features, genetic findings, and its response to biologic therapy.

**Case:** A 1.6-year-old girl presented with eyelid and lower limb edema, proteinuria (3+), and was diagnosed with steroid-sensitive but frequently relapsing nephrotic syndrome. At 1 year 9 months, she developed red, ring-shaped plaques with silvery scales and pinpoint pustules on the trunk, face, limbs, and perineum. Inflammatory markers (ESR, CRP, IL-6, TNF- $\alpha$ ) were markedly elevated. Whole-exome sequencing revealed a homozygous IL36RN variant (c.115+6T>C). Her father carried the same homozygous variant and had chronic toe skin lesions and nail damage since youth; her mother was a heterozygous carrier. IL-36Ra expression was absent in skin lesions specimen and reduced in urinary epithelial cells of the child. At 2 years 2 months, Secukinumab was initiated with rapid resolution of erythema and pustules.

**Conclusions:** We describe the first documented case of GPP concurrent with INS in a young child carrying a homozygous IL36RN mutation. Secukinumab showed promising efficacy in controlling GPP in this patient.

### Points of discussion:

1. This case expands the phenotypic spectrum of IL36RN mutations with comorbidity of INS.
2. Early use of IL-17 inhibition (secukinumab) appears effective and well-tolerated in very young children with GPP.

**Keywords:** generalized pustular psoriasis; IL36RN gene mutation; secukinumab; nephrotic syndrome; biologics



P3-6

## Rituximab combined with daratumumab in the treatment of a child with multidrug-resistant nephrotic syndrome

Ke Xu, Baige Su, Xiaoyu Liu, Xuhui Zhong, Huijie Xiao, Fang Wang

Department of Pediatrics, Peking University First Hospital, Beijing, China

**Backgrounds:** Primary nephrotic syndrome (PNS) is a common glomerular disease in children, with a considerable proportion of patients developing steroid-resistant or frequently relapsing nephrotic syndrome (SRNS/FRNS) that is unresponsive to conventional immunosuppressive therapies and anti-CD20 monoclonal antibody treatment. B cells and long-lived plasma cells play synergistic pathogenic roles in the progression of nephrotic syndrome. Unlike short-lived plasmablasts, long-lived plasma cells, a major source of antibodies, are unresponsive to anti-CD20 immunosuppressive treatments and highly express CD38. Daratumumab is a human monoclonal antibody that targets CD38.

**Case:** We report a 6-year-old male child who was diagnosed with focal segmental glomerulosclerosis (FSGS) at 2 years of age and presented with steroid-resistant nephrotic syndrome (SRNS). Initially, glucocorticoids combined with tacrolimus achieved sustained remission of NS for 2 years, and glucocorticoids were successfully withdrawn. However, 1.5 years later, he experienced a relapse of NS, complicated by positive anti-nephrin antibodies. The patient was resistant to multiple drugs, including high-dose methylprednisolone pulse therapy, tacrolimus, cyclosporine, mycophenolate mofetil, cyclophosphamide, and rituximab, despite the normalization of anti-nephrin antibody levels after treatment. Due to long-term massive proteinuria and glucocorticoid administration, he had a body weight of only 15 kg, accompanied by adverse effects such as short stature, steroid myopathy, and increased susceptibility to infections. Additionally, he had received calcineurin inhibitor (CNI) therapy for more than 4 years. After obtaining informed consent from his parents, the child received a low dose of rituximab (150mg/m<sup>2</sup>) followed by daratumumab 2 weeks later. During the daratumumab infusion, the patient developed gastrointestinal adverse reactions, manifested as vomiting and diarrhea. The symptoms were alleviated after slowing down the infusion rate, and the infusion was completed successfully. At the 1-month follow-up, the patient's 24-hour urinary protein decreased significantly from 2.18 g to 0.17 g, with normalized serum albumin levels. glucocorticoids had been gradually tapered and discontinued, and cyclosporine was un-



der tapering.

**Conclusions:** For pediatric patients with multidrug-resistant nephrotic syndrome, combined therapy with rituximab and daratumumab may be a promising therapeutic option.

**Points of discussion:** Which patients with PNS may be considered for combined rituximab and daratumumab therapy?

**Keywords:** Nephrotic syndrome, anti-CD20 monoclonal antibody, daratumumab



P3-7

## Renal-predominant pediatric primary Sjögren's syndrome complicated by EBV-associated immune dysregulation and serositis: a case report

Ling Hou, Yue Du

Department of Pediatrics, Shengjing Hospital of China Medical University, Shenyang, China

**Backgrounds:** Primary Sjögren's syndrome (pSS) is a rare systemic autoimmune disease in children, often characterized by extraglandular involvement and atypical clinical presentations. Renal involvement is uncommon in pediatric pSS and may precede classical sicca symptoms, posing significant diagnostic challenges. Furthermore, viral infections such as Epstein-Barr virus (EBV) may trigger immune dysregulation and exacerbate systemic manifestations. We report a pediatric case of pSS presenting initially with renal involvement and subsequently complicated by EBV-associated immune disturbance and serositis.

**Case:** An 8-year-old girl initially presented in 2023 with intermittent gross hematuria, proteinuria, and eyelid edema. Renal biopsy revealed tubulointerstitial nephritis combined with atypical membranous nephropathy, characterized by mild mesangial proliferation, podocyte injury, and granular IgG-dominant immune complex deposition along glomerular capillary walls. She showed response to glucocorticoid therapy.

In mid-2025, the patient developed recurrent fever, generalized lymphadenopathy, cough, facial edema, and progressive dyspnea. Imaging studies demonstrated bilateral pleural effusions and mild pericardial effusion, accompanied by hypoalbuminemia and elevated inflammatory markers. Serological tests showed high-titer anti-nuclear antibodies (1:5120) and strong positivity for anti-SSA/Ro52 antibodies. Salivary gland scintigraphy revealed severely impaired excretory function, and ophthalmologic examination confirmed dry eye, leading to a definitive diagnosis of primary Sjögren's syndrome.

Given the severe systemic involvement, the patient received systemic glucocorticoids combined with four courses of rituximab, resulting in transient clinical improvement and partial resolution of serositis. However, three months after rituximab therapy, pleural and pericardial effusions recurred, indicating persistent disease activity and inadequate disease control with B-cell-targeted therapy alone.

The treatment strategy was subsequently escalated to high-dose intravenous methylprednisolone pulse therapy combined with cyclophosphamide, under close monitoring. At the time of reporting, the patient re-

mains under active treatment, with gradual improvement of respiratory symptoms and stabilization of renal function.

**Conclusions:** This case highlights that pediatric pSS may initially present with predominant renal involvement, preceding classical sicca features by years. EBV-associated immune dysregulation may contribute to disease exacerbation and systemic complications such as serositis. Early recognition, comprehensive immunological evaluation, and timely immunomodulatory therapy are crucial for improving outcomes in pediatric pSS with multi-organ involvement.

**Points of discussion :**

1. Renal involvement may be the initial and dominant manifestation of pediatric pSS.
2. Atypical membranous nephropathy combined with interstitial nephritis should prompt evaluation for autoimmune etiologies.
3. EBV infection may act as a trigger for immune dysregulation and systemic disease flare.
4. Recurrent serositis after rituximab therapy suggests that pediatric primary Sjögren's syndrome with prominent inflammatory phenotypes may require broader immunosuppressive strategies beyond B-cell depletion alone.

**Keywords:** primary Sjögren's syndrome; EBV; serositis



P3-8

## A Complex Case of Recurrent Hematuria, Proteinuria, and Chronic Diarrhea in an Adolescent Male: A Multidisciplinary Challenge

MiLan, Wang Hui

National Center for Children's Health, Beijing Children's Hospital, Capital Medical University, Beijing, China

**Backgrounds:** Diagnosing adolescents with overlapping symptoms of recurrent hematuria, proteinuria, chronic diarrhea, and joint pain poses significant challenges, often requiring a multidisciplinary approach to differentiate between infectious, autoimmune, inflammatory, and genetic etiologies.

**Case:** A 15-year-old male presented with a 1-year history of intermittent fever, chronic diarrhea (2-5 semi-formed stools/day), and recurrent gross hematuria associated with lumbar pain. His history included left testicular torsion and appendicitis surgeries. Multiple hospitalizations involved treatments for suspected urinary tract infections (UTIs) with various antibiotics (e.g., meropenem, aztreonam, amikacin), yielding transient improvements. Repeated urine cultures frequently grew *Serratia marcescens*. Investigations revealed proteinuria (up to 4.5g/24h), elevated fungal D-glucan, positive stool *C. difficile* toxin B gene, and 胡桃夹现象 (Nutcracker phenomenon) on imaging. Renal biopsy showed minimal change glomerulopathy on light microscopy and focal glomerular basement membrane lesions on electron microscopy. Extensive workup, including autoimmune serology, gastrointestinal endoscopy, and genetic testing (whole exome sequencing), revealed variants of uncertain significance in the MEFV gene but no definitive diagnosis. Immunological and metabolic screenings were largely unremarkable. Despite aggressive and sequential antimicrobial therapies, symptoms of gross hematuria, diarrhea, and joint pain persisted.

**Conclusions:** This case highlights a complex, multisystemic disorder in an adolescent, characterized by persistent hematuria, proteinuria, and chronic diarrhea, resistant to conventional antimicrobial therapies. The findings suggest a possible underlying immune dysregulation or a rare genetic disorder rather than a typical infectious process, as evidenced by the equivocal genetic results and the lack of response to targeted treatments.

**Points of discussion:**

1. What is the unifying diagnosis for this combination of renal, gastrointestinal, and joint manifestations? Are the MEFV gene variants clinically significant?

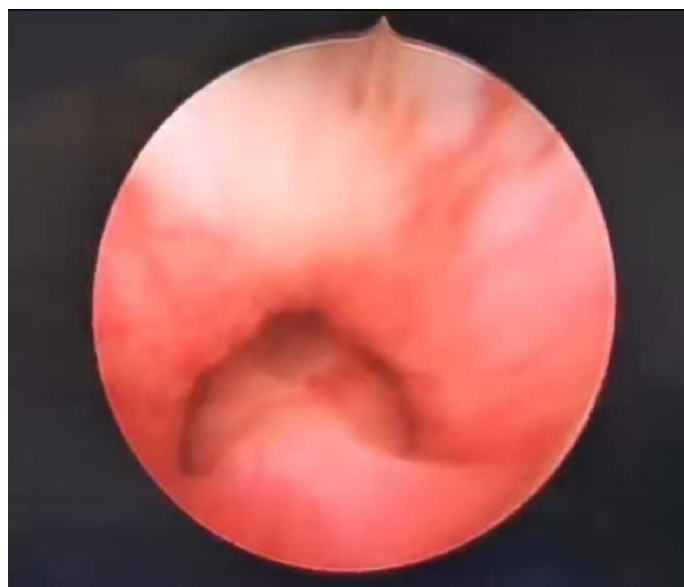2. What further investigations are crucial for clarifying the etiology (e.g., repeat renal biopsy, functional immune assays, or targeted genetic panels)?
3. What should be the subsequent management strategy, considering the poor response to previous therapies? Should immunosuppressive therapy be considered empirically?


**Keywords:** Hematuria, proteinuria, diarrhea, fungal infection, recurrent infections

基因	染色体位置	转录本外显子	核苷酸氨基酸	纯合/杂合	正常人频率	预测	ACMG致病性分析(分值)	疾病/表型(遗传方式)	变异来源
<i>MEF</i> V	chr16:329 9468 <sup>[1]</sup>	NM_0002 43.3:exon 3	c.1223G>A (p.Arg408Gln)	het	0.0634615	LB	Uncertain (0)	1.常染色体显性家族性地中海热(AD) 2.急性发热性嗜中性皮肤病(AD) 3.家族性地中海热(AR)	母亲
<i>MEF</i> V	chr16:329 9586 <sup>[2]</sup>	NM_0002 43.3:exon 3	c.1105C>T (p.Pro369Ser)	het	0.0886889	LB	Uncertain (0)	1.常染色体显性家族性地中海热(AD) 2.急性发热性嗜中性皮肤病(AD) 3.家族性地中海热(AR)	母亲

6		0	5.32	VUS 1	chr4:103455110	NM_003998.4	het	-	正常	
NFKB1	0	0	0.72	PM2_Suppo...	c.159+68A>T	intron4	21/15(0.417)	0	101.95	AD/罕见变异型免疫缺陷12型
外显不全或印记	0	0	1	自动	p.?		36	未知	26.93	
VSLF					unknown			未知		

4		8	5.32	VUS 1	chr4:103528967	NM_003998.4	het	-	正常	
NFKB1	0	0	0.72	PM2_Suppo...	c.2227+59T>G	intron19	34/34(0.5)	0	101.95	AD/常见变异型免疫缺陷12型
外显不全或印记	0	0	1	自动	p.?		68	未知	26.93	
VSLF					unknown			未知		





P4-1

## A case of C3 glomerulonephritis with normalized C3 levels following initiation of oral levothyroxine therapy for Hashimoto's thyroiditis

**Yooka Nam<sup>1</sup>, Shunsuke Shinozuka<sup>1</sup>, Bunshiro Akikusa<sup>2</sup>, Ryugo Hiramoto<sup>1,3</sup>**

<sup>1</sup>Department of Pediatrics, Children's Medical Centre, Matsudo City General Hospital, Japan, <sup>2</sup>Department of Pathology, Matsudo City General Hospital, Japan, <sup>3</sup>Cantabile Pediatric Clinic, Japan

**Backgrounds:** C3 glomerulonephritis (C3GN) is a nephritis caused by excessive activation of the complement metabolic pathway. The severity varies, but it progresses chronically. Low complement levels are characteristic findings in blood tests, and low complement levels are reported to persist in approximately half of cases. We report a case in which Hashimoto's thyroiditis developed during C3GN therapy, and C3 levels normalized after initiating levothyroxine oral administration.

**Case:** An 18-year-old female. At age 14, a school urine screening indicated positive for microscopic hematuria, prompting her to visit a previous doctor. Microscopic hematuria (RBC 30-49 per HPF), ASO 358 IU/mL, C3 6 mg/dL, and hypocomplementemia with elevated ASO levels were observed. Then, post-infectious acute glomerulonephritis was first suspected. However, due to persistently low C3 levels for over 8 weeks, she was referred to our hospital for a kidney biopsy. Histopathological examination revealed diffuse endocapillary and mesangial hypercellularity, with significant C3 deposition. Electron microscopy revealed electron dense deposits (EDD) in the mesangial area as well as in the subendothelial and subepithelial regions. No EDD was observed such as that seen in dense deposit disease (DDD), and no hump was present. Therefore, C3GN was definitively diagnosed.

She has been treated with two courses of methylprednisolone pulse therapy, followed by oral prednisolone (PSL), mycophenolate mofetil, and lisinopril. Neither proteinuria nor renal dysfunction was observed throughout the course of treatment, and PSL was successfully discontinued two years after the treatment initiation. At that point, microscopic hematuria (RBC 20 per HPF or less) persisted, and C3 levels remained low at approximately 30 mg/dL.

At age 16, she complained of fatigue and visited another hospital, blood test shows TSH 86.6  $\mu$ IU/mL, FT3 1.98 pg/mL, FT4 0.48 ng/mL, anti-TPO antibody >600 IU/mL, ultrasound examination revealed thyroid enlargement, Hashimoto's thyroiditis was diagnosed, and oral levothyroxine therapy was initiated. Following initiation



of treatment, C3 levels showed an upward trend, and within approximately one year, C3 levels normalized and hematuria resolved.

**Conclusions:** We report a case in which Hashimoto's thyroiditis developed during C3GN therapy, and after initiating oral levothyroxine, C3 levels normalized and hematuria resolved.

**Points of discussion:** Any idea regarding the association between the amelioration of C3GN and Hashimoto's thyroiditis and/or levothyroxine?

**Keywords:** C3 glomerulonephritis, Hashimoto's thyroiditis, levothyroxine

## P4-2

## SLE-associated thrombotic microangiopathy with refractory pericardial effusion and cardiac tamponade rescued by pericardial fenestration and rituximab: a case report

**Fumika Yurugi<sup>1</sup>, Toru Uchimura<sup>2</sup>, Yu Kamigaki<sup>2</sup>, Jotaro Harada<sup>3</sup>, Seira Hattori<sup>1</sup>, Ikuyo Ito<sup>1</sup>, Nishimura Kenichi<sup>1</sup>, Tomo Nozawa<sup>1</sup>, Satoshi Fujii<sup>3</sup>, Junki Koike<sup>4</sup>, Shuichi Ito<sup>1,2</sup>**

<sup>1</sup>Department of Pediatrics, Graduate School of Medicine, Yokohama City University, Japan, <sup>2</sup>Department of Pediatrics, Yokohama City University Medical Center, Japan, <sup>3</sup>Department of Pathology, Graduate School of Medicine, Yokohama City University, Japan, <sup>4</sup>Department of Pathology, Graduate School of Medicine, St. Marianna University School of Medicine, Japan

**Backgrounds:** Thrombotic microangiopathy (TMA) is a recognized complication of systemic lupus erythematosus (SLE). No established treatment supported by high-level evidence exists for SLE-associated TMA (SLE-TMA), except in cases complicated by thrombotic thrombocytopenic purpura (TTP) or atypical hemolytic uremic syndrome (aHUS). SLE-TMA carries a poor prognosis, with a reported mortality rate of 46%–62%, compared with 12% for TTP. Therefore, SLE-TMA is often treated with plasma exchange and/or rituximab. We report a case of SLE-TMA with refractory pericardial effusion and cardiac tamponade that was successfully managed with pericardial fenestration and rituximab.

**Case:** A 15-year-old girl with no significant past medical history developed eyelid and lower leg edema 3 weeks before admission. She was admitted to a previous hospital with suspected nephrotic syndrome but was diagnosed with SLE based on elevated anti-double-stranded DNA antibodies, hypocomplementemia, and other findings. She was treated with prednisolone 60 mg/day and intravenous cyclophosphamide. However, renal dysfunction, severe hypertension, and pericardial effusion subsequently developed. She was transferred to our institute on hospital day 17 (D17). TMA was diagnosed based on thrombocytopenia, schistocytes, and acute kidney injury. Plasma exchange and mycophenolate mofetil were initiated on D20. Serum creatinine and thrombocytopenia improved after 7 days of plasma exchange; however, thrombocytopenia worsened again thereafter. TTP was ruled out based on normal ADAMTS13 activity. Eculizumab was then administered on three occasions. Despite this, TMA progressed, and plasma exchange was restarted on D62. Plasma exchange was continued daily for 16 days, followed by five sessions on alternate days, but pericardial effusion and renal dysfunction worsened. Plasma exchange was resumed, and two additional doses of eculizumab were administered without improvement. Anti-complement factor H antibodies and pathogenic variants associated



with aHUS were not detected. Prerenal acute kidney injury secondary to cardiac tamponade was suspected. A pericardial drain was placed on D94, resulting in transient improvement in serum creatinine. Rituximab was initiated on D98. Because the pericardial effusion increased again, video-assisted thoracoscopic pericardial fenestration with chest tube placement was performed on D106. Rituximab was administered at a dose of 375 mg/m<sup>2</sup> weekly for a total of three doses. The pericardial effusion gradually decreased, and the chest tube was removed on D133. Renal biopsy performed on D178 revealed ISN/RPS class IV lupus nephritis with endothelial injury consistent with TMA. Two additional courses of steroid pulse therapy and one course of intravenous cyclophosphamide pulse therapy were administered, and prednisolone was tapered to 14 mg/day. She was discharged on D235.

**Conclusions:** In patients with SLE-associated TMA complicated by refractory pericardial effusion, early administration of rituximab in addition to pericardial fenestration should be considered.

**Points of discussion:** The efficacy of pericardial fenestration in refractory pericardial effusion associated with TMA, and the efficacy of rituximab in non-TTP/aHUS TMA in SLE.

**Keywords:** systemic lupus erythematosus, Thrombotic microangiopathy, rituximab

P4-3

## Atypical Post-Infectious Glomerulonephritis with Persistent Complement Activation

Jiwon Jung, Joo Hoon Lee

Department of Pediatrics, Asan Medical Center Children's Hospital, University of Ulsan College of Medicine, Seoul, Korea

**Background:** Post-infectious glomerulonephritis (PIGN) is an immune complex-mediated glomerular injury that typically resolves spontaneously. However, a minority of patients exhibit persistent alternative pathway (AP) activation, leading to an atypical course with ongoing hematuria and proteinuria, which may progress to advanced kidney damage. We present a case of this atypical PIGN.

**Case:** A 12-year-old male presented with two episodes of recurrent asymptomatic gross hematuria following upper respiratory tract infections within a one-year period. Kidney ultrasonography (US) from outside hospital showed nonspecific finding. At presentation, he had microscopic hematuria (RBC 11-20/HPF, 85% dysmorphic) and mild proteinuria (UPCR 0.513 g/g) with normal kidney function (serum Cr 0.54 mg/dL, cystatin C 0.99 mg/L, eGFR 118 mg/ml/1.73 m<sup>2</sup>). Initial laboratory findings revealed an elevated antistreptolysin O antibody (ASO) titer (662.9 IU/mL), normal C4 (13.78 mg/dL), but decreased C3 (49.3 mg/dL) and CH50 (33.2 U/mL) levels. Since complement assays were not performed during the initial episodes, the duration of C3 depression was unknown. A kidney biopsy was performed due to repeated episodes and suspected AP activation. The biopsy showed diffuse glomerular enlargement with cellular proliferation and subepithelial deposits, consistent with acute PIGN. Although some glomeruli showed focal segmental endocapillary leukocytic infiltration, generally glomerular capillary walls were thin and delicate with well-opened lumen with subepithelial fusciphilic deposits. Immunofluorescence was positive for C3 granular deposits and negative for IgG. Electron microscopy revealed subepithelial humps and small intramembranous/mesangial deposits. Due to the persistence of symptoms for over a year—unlike typical self-limiting PIGN—RAS inhibitors (RASi) and immunosuppressive therapy were initiated. Azathioprine was initially used but switched to mycophenolic acid after one month due to minimal clinical response. After five months of mycophenolic acid, C3 levels recovered to 50 mg/dL and UPCR improved to <0.2 g/g, although microscopic hematuria partially persists, and ASO levels remained persistently elevated (404.9 IU/mL). Kidney function remained stable within normal limits. Genetic evaluation for



the underlying etiology of alternative pathway activation is currently in progress.

**Conclusions:** We report a 12-year-old child with PIGN who exhibited an atypical clinical course. Further evaluation for abnormalities in the alternative pathway of the complement system may be essential for predicting prognosis and preserving long-term kidney function.

**Point of discussion:**

- 1) Do PIGN and C3GN exist within a clinical spectrum of a continuum? Given the patient's clinical trajectory, it is worth discussing whether 'atypical PIGN' is the most appropriate diagnosis, or if the persistent C3 activation indicates an underlying C3 glomerulopathy.
- 2) What is the indication of treatment in this case of atypical PIGN in context persistent C3 activation and consumption?

## P4-4

## Rapidly Progressive Poststreptococcal Glomerulonephritis in a Child: Diagnostic Pitfalls in an Atypical Presentation

Tae-Yang Choi, Hyung Eun Yim

Department of Pediatrics, Korea University Ansan Hospital, Korea University College of Medicine, Seoul, Republic of Korea

**Background:** Poststreptococcal glomerulonephritis (PSGN) is a common cause of acute glomerulonephritis in children and is generally associated with a favorable prognosis. However, rare cases may present with an atypical and severe course, including crescentic transformation, acute kidney injury, and systemic involvement. In the setting of massive glomerular bleeding, urine color and red blood cell (RBC) morphology may not reliably indicate a glomerular origin of hematuria, and the presence of combined hypocomplementemia or severe anemia may further complicate the diagnostic evaluation. We report a child with severe PSGN to highlight these diagnostic pitfalls and their clinical implications.

**Case report:** A 10-year-old boy was admitted with a 7-day history of edema and a 4-day history of gross hematuria. At birth, the patient had bilateral second-third toe syndactyly and urogenital anomalies involving the testes, penis, and hypospadias. He underwent corrective surgery at approximately 1 year of age and has been followed at a speech and language center for developmental delay. The patient's younger sibling has more severe developmental delay, and the mother has a history of syndactyly. There was no family history of renal disease. Eleven days prior to admission, he experienced low-grade fever and sore throat. One week before admission, facial and generalized edema developed, followed by reddish gross hematuria beginning four days prior to admission, prompting hospitalization via the emergency department. He had gained approximately 6–7 kg in body weight over one week. On admission, his blood pressure was 139/78 mmHg (above the 99th percentile for age), heart rate 106 beats/min, respiratory rate 22 breaths/min, and body temperature 36.7° C. Physical examination revealed a puffy face, both costovertebral angle tenderness, and bilateral pitting edema of the lower extremities. Chest radiography demonstrated bilateral pleural effusions and bilateral lower lung field consolidation. Initial laboratory findings were as follows: a white blood cell count of 8,900/mm<sup>3</sup>, hemoglobin 8.2 g/dL, platelet count 279 × 10<sup>3</sup>/mm<sup>3</sup>, blood urea nitrogen 87.6 mg/dL, serum creatinine 1.8 mg/dL (estimated glomerular filtration rate [eGFR], 29.2 mL/min/1.73 m<sup>2</sup>), uric acid 12.5 mg/dL, total protein 5.2 g/dL, albumin 2.9 g/dL, total cholesterol 174 mg/dL, C-reactive protein 0.76 mg/dL, and NT-proBNP >35,000 pg/mL.



Urinalysis revealed heavy proteinuria (urine protein-to-creatinine ratio [uPCR] 11.9) and non-dysmorphic hematuria (RBCs >60/high-power field, dysmorphic RBC 0%). Autoimmune serologic testing showed markedly decreased complement levels (C3 18 mg/dL, C4 3.9 mg/dL, CH50 <10 U/mL), with negative antinuclear antibody, anti-double-stranded DNA antibody, and anti-neutrophil cytoplasmic antibodies. The anti-streptolysin O titer was elevated at 480 IU/mL. Renal ultrasonography demonstrated increased renal echogenicity, ascites, and pleural effusion. On hospital day 2, the hemoglobin level further decreased to 7.4 g/dL with persistent severe gross hematuria, necessitating RBC transfusion. By hospital day 3, renal function deteriorated further, with eGFR declining to 18 mL/min/1.73 m<sup>2</sup>. Given suspicion of rapidly progressive glomerulonephritis (RPGN), steroid pulse therapy was initiated and a kidney biopsy was performed. Continuous intravenous nicardipine and furosemide were administered for hypertension and oliguria. Echocardiography on admission revealed pulmonary hypertension (pressure gradient 39 mmHg), dilated pulmonary artery, and mild left atrial enlargement. Prolonged QT interval was noted on hospital day 4 (corrected QT 548 ms) and persisted until hospital day 12. On hospital day 9, the patient developed partial seizures accompanied by eyeball deviation. Brain magnetic resonance imaging demonstrated focal infarctions in both frontal cortices and the left temporal cortex, suggestive of a thromboembolic etiology. EEG revealed diffuse mild delta background slowing (left >right) with frequent near-periodic spike-wave discharges. Seizure episodes recurred several times daily, lasting 1–2 minutes, over the subsequent three days. Marked elevations in urinary (19 μg/mL) and serum (9.1 mg/L) β2-microglobulin levels were observed. On hospital day 13, the patient developed fever, and respiratory viral testing was positive for influenza A. Following maintenance therapy with levetiracetam, seizures resolved. Gross hematuria persisted as bright-red urine for over 3 weeks after admission, followed by light cola-colored urine for approximately 1–2 additional weeks. C3 and C4 levels remained decreased for 12 days and normalized by hospital day 18. From hospital day 18, liver function tests became elevated, with AST/ALT increasing to 72/265 IU/L and GGT to 242 IU/L. The levels initially decreased but rose again 3 days after discharge, reaching AST/ALT 116/341 IU/L and GGT 221 IU/L. During the 5-week hospitalization, urinary sediment was examined 12 times; dysmorphic RBCs accounted for 10–25% in 4 samples, while no dysmorphic RBCs were detected in the remaining 8 samples (67%). Renal biopsy performed at admission revealed crescentic glomerulonephritis consistent with PSGN, accompanied by severe acute tubulointerstitial nephritis. With continued oral corticosteroid therapy, antihypertensive agents (amlodipine and enalapril), anticonvulsant therapy, and lipid-lowering medication, renal function gradually improved, with eGFR recovering to 73 mL/min/1.73 m<sup>2</sup>. The patient was discharged on hospital day 35 despite persistent hematuria and residual proteinuria (uPCR 2.39). Given the family history of developmental delay, past genitourinary anomalies, and syndactyly, along with multisystem involvement in PSGN, whole-exome sequencing of the patient and both parents is currently being performed to evaluate for an underlying genetic disorder.

**Conclusion:** This case highlights an unusually severe and atypical course of PSGN complicated by crescentic



transformation, tubulointerstitial nephritis, and multisystem involvement, underscoring the need for early recognition and individualized treatment in pediatric patients.

**Points of discussion**

1. How can massive glomerular bleeding lead to the paradoxical presentation of bright-red urine with predominantly isomorphic RBCs and transfusion-requiring anemia, and what are the implications for diagnosing glomerular hematuria in RPGN?
2. How should combined hypocomplementemia of C3, C4, and CH50 be interpreted in PSGN, particularly with respect to differential diagnosis and disease severity?
3. What is the clinical significance of concomitant crescentic glomerulonephritis and severe acute tubulointerstitial nephritis in PSGN?



P4-5

## Effective Eculizumab Therapy in Pediatric SP-HUS Following T-Antigen-Negative Plasma Exchange

Lu Yin, Yue Du

Department of Pediatric Nephrology, Shengjing Hosiptal of China Medical University, Shenyang, Liaoning, China

**Backgrounds:** Streptococcus pneumoniae-associated HUS (SP-HUS) is rare and severe; only 10 eculizumab-treated cases are reported, with uncertain efficacy.

**Case:** A 3-year-old boy with SP-HUS, severe pneumonia, and empyema received antibiotics, CRRT, methylprednisolone, and 5 sessions of T-antibody-negative plasma exchange, showing partial improvement but persistent anuria. Complement studies revealed low C3 (0.57 g/L), low C4 (0.11 g/L) and markedly elevated sC5b-9 (845 ng/mL). After meningococcal vaccination, eculizumab (600 mg IV) was given on day 7. Urine output resumed within 24 hours; LDH, platelets, and urine volume normalized by day 3; creatinine normalized by day 20.

**Conclusions:** Eculizumab is effective in SP-HUS with complement activation, even after suboptimal response to plasma exchange. Elevated sC5b-9 may guide its use.

**Points of discussion:** Globally, only 10 pediatric SP-HUS cases treated with eculizumab have been reported: 6 recovered renal function by discharge, 4 progressed to CKD. Most received eculizumab within 1–7 days of onset. Our patient, treated on day 7 after partial response to plasma exchange, showed rapid recovery—supporting its use when complement activation is evident (elevated sC5b-9). Eculizumab has not been linked to worsening pneumococcal infection.

**Keywords:** Streptococcus pneumoniae-associated HUS, eculizumab, T-antibody-negative plasma exchange, complement activation

P4-6

## The Co-existence of BK Virus Nephropathy with Acute Rejection in a Pediatric Renal Allograft Recipient

**Baige Su<sup>1</sup>, Ke Xu<sup>1</sup>, Suxia Wang<sup>2</sup>, Yali Ren<sup>2</sup>, Wei Wang<sup>3</sup>, Fang Wang<sup>1</sup>, Xuhui Zhong<sup>1</sup>**

<sup>1</sup>Department of Pediatric Nephrology, Peking University First Hospital, China, <sup>2</sup>Laboratory of Electron Microscopy, Ultrastructural Pathology Center, Peking University First Hospital, China, <sup>3</sup>Department of Pathology, Peking University First Hospital, China

**Backgrounds:** BK virus nephropathy (BKVN) is a major cause of renal allograft loss. Cases of concomitant acute rejection (AR) and BKVN are rare, especially in children.

**Case:** A 7-year-old boy underwent kidney transplantation 2 years prior to presentation for congenital anomalies of the kidney and urinary tract (CAKUT) with pre-transplant chronic kidney disease stage 5. One year before admission, he was diagnosed with post-transplant Epstein-Barr virus (EBV)-associated lymphoproliferative disorder (polymorphic post-transplant lymphoproliferative disorder, PTLD). His clinical condition was well controlled and stabilized after four doses of rituximab therapy. He was admitted to our hospital due to elevated serum creatinine and BK viremia, and was administered 1 g/kg intravenous immunoglobulin (IVIG). One month later, he underwent renal allograft biopsy due to persistent elevation of serum creatinine (138  $\mu\text{mol/L}$ ). Immunological evaluations, including immunoglobulin levels, complement components, and CD4+ T-cell counts, were within normal limits. Serological testing revealed an elevated BK virus (BKV)-DNA viral load ( $4.06 \times 10^5$  copies/mL), whereas EBV-DNA and JCV-DNA viral loads were within normal limits. Trough tacrolimus concentrations ranged from 3.0 to 6.4 ng/mL, and HLA-specific donor-specific antibodies (DSA) were negative. Histochemical staining showed SV40-T antigen positivity in approximately 10% of renal tubular epithelial cells. Histological findings demonstrated severe tubulointerstitial nephritis with tubulitis, consistent with polyomavirus nephropathy (PyVN) complicated by acute T cell-mediated rejection (ATCMR, grade IB); PTLD remained to be excluded. He received 1 g/kg IVIG followed by intravenous methylprednisolone pulse therapy (5 mg/kg per dose, 3 doses). A repeat renal allograft biopsy was performed after serum creatinine decreased to 98.7  $\mu\text{mol/L}$  and BKV-DNA became negative. The second biopsy showed acute T cell-mediated rejection (grade IB), with no morphological evidence of BKVN. Immunohistochemical staining revealed CD3 (++) , CD20 (+), CD21 (+), CD4 (40%+) , CD8 (60%+) . In situ hybridization for EBV-encoded small RNA (EBER) was negative. SV40T and C4d staining on peritubular capillaries (PTC) were both negative. He was then treated with another



course of intravenous methylprednisolone pulse therapy (5 mg/kg per dose, 3 doses), followed by oral prednisone at 0.5 mg/kg/day. After treatment, serum creatinine decreased to 73.5  $\mu$ mol/L, and BKV-DNA remained negative.

**Conclusions:** Early diagnosis and appropriate management of concomitant acute rejection and BK virus nephropathy can lead to favorable clinical outcomes.

**Points of discussion:** Concomitant BKVN and acute T cell-mediated rejection presents diagnostic and therapeutic challenges in pediatric kidney transplant recipients, due to overlapping clinical features and opposing therapeutic strategies. Serial renal allograft biopsy, combined with BKV-DNA viral load monitoring and immunohistochemical markers, is essential for the accurate diagnosis and dynamic evaluation of concomitant BKVN and acute rejection. Individualized therapeutic strategies, including appropriate adjustment of immunosuppression, IVIG, and steroid pulse therapy, can achieve favorable graft function and viral control in pediatric patients with concurrent BKVN and acute T cell-mediated rejection.

**Keywords:** pediatric, BK virus nephropathy, acute T cell-mediated rejection

P4-7

## Transplant-associated Thrombotic Microangiopathy after hematopoietic stem cell transplantation in children-a case report

Haiyan Wang<sup>1,2</sup>, Weiping Tan<sup>1</sup>, Bihong Zhang<sup>1</sup>, Ke Huang<sup>1</sup>, Jianpei Fang<sup>1</sup>, Liangzhong Sun<sup>2</sup>

<sup>1</sup>Sun Yat-sen Memorial Hospital, Sun Yat-sen University, Guangzhou, China, 510120,

<sup>2</sup>Nanfang Hospital, Southern Medical University, Guangzhou, China, 510515

**Backgrounds:** Transplant-associated Thrombotic Microangiopathy (TA-TMA) after hematopoietic stem cell transplantation (HSCT) in children is a life-threatening complication, primarily characterized by microvascular thrombosis caused by endothelial cell damage. The prognosis of TA-TMA in children is extremely poor, with a mortality rate of 50%-90%. The 1-year overall survival (OS) rate for patients with TA-TMA is significantly lower than that of children without TMA.

**Case:** The boy developed severe aplastic anemia at 12 years old, complicated by septic shock. After undergoing HSCT with 6/10 HLA-matched maternal haploid at the age of 12 years and 3 months, the patient developed septic, acute Graft-versus-host disease (GVHD) and acute kidney injury stage 3). He was treated with various antibiotics for anti-infection and immunosuppressants [such as cyclosporine A, tacrolimus, mycophenolate mofetil (MMF), Cyclophosphamide and rituximab], glucocorticoids and plasma exchange for anti-GVHD. At the age of 12 years and 8 months, the patient's infection gradually came under control, and GVHD was improved except renal injury, with serum creatinine (Scr) 202-229  $\mu\text{mol/L}$ , urine red blood cells (URBC) 0-35 cells/ $\mu\text{L}$  and urine protein-to-creatinine ratio (UPCR) 1.17 mg/mg. At the age of 13 years and 1 months, his Scr rose to 289  $\mu\text{mol/L}$  due to infection. Anti-infection treatment and besudil were administered, combination with MMF and glucocorticoids. The Scr decreased to 120-129  $\mu\text{mol/L}$ . At the age of 14 years and 1 month, MMF was attenuated (0.25 g qod), and his Scr rose again (193-246  $\mu\text{mol/L}$ ), with URBC 102-230 cells/ $\mu\text{L}$ , UPCR 0.86 mg/mg. Renal biopsy revealed severe chronic tubulointerstitial damage, occasional microthrombi, and possible early membranous nephropathy. Immunofluorescence showed IgG (++) and electron microscopy revealed possible TMA damage (Figure 1). Complement factor testing indicated positive CFI antibody and normal serum C5b-9. His Hb 109 g/L, platelet  $191 \times 10^9/\text{L}$ , no red blood cell fragments were observed in peripheral blood cells, LDH 192 U/L. Considering TA-TMA, the MMF dosage was increased (0.25 g bid) and methylprednisolone pulse therapy (0.5g  $\times$  3d) was administered, with prednisone tapering down. 2 months later, the Scr was 170  $\mu\text{mol/L}$ , and



URBC 6 cells/ $\mu$ L, UPCR 0.25 mg/mg.

**Conclusions:** TA-TMA in children may occur 2 years after HSCT. The etiology is complex and may be related to infection, CNI drugs, and GVHD. It can manifest as a localized renal injury, and treatment with methylprednisolone pulse therapy and MMF has shown significant efficacy.

**Points of discussion:** Endothelial cell injury is an early event in TA-TMA. This injury leads to a procoagulant state and activation of the complement system, subsequently forming microthrombi. The key risk factors for the occurrence of TA-TMA include severe transplantation-associated acute GVHD, high-dose chemotherapy/radiotherapy, and medications. In this case, TMA occurred nearly two years after transplantation after reduction in anti-GVHD drug but did not occur during acute GVHD. This suggests that TMA can also occur during the chronic GVHD phase. The key to treating TA-TMA lies in "removing the cause" and "suppressing complement activation," which can significantly improve survival rates. In this case, complement factor testing revealed that serum C5b-9 levels were not elevated, thus no complement inhibitor treatment was administered. Instead, high-dose steroid pulse therapy and MMF treatment were given, leading to improvement in renal function.

**Keywords:** Key words: Thrombotic Microangiopathy, hematopoietic stem cell transplantation, children

P4-8

## A Case of Kidney Transplantation in a Patient with Central Diabetes Insipidus

**Rika Fujimaru, Takahiro Fujii, Ryota Sakai**

Division of Pediatric Endocrinology, Metabolism and Nephrology, Osaka City General Hospital, Osaka, Japan

**Backgrounds:** Central diabetes insipidus (CDI) is characterized by polyuria and hypernatremia due to impaired secretion of arginine vasopressin (AVP). However, patients with end-stage renal disease (ESRD) usually present with oliguria or anuria; therefore, the need for desmopressin (DDAVP) is rare even in those with concomitant CDI. In contrast, urine output recovers after kidney transplantation, making fluid and electrolyte management particularly important in recipients with CDI. We report a case of preemptive kidney transplantation in a recipient with CDI who developed ESRD due to Alport syndrome and had been managed with DDAVP following surgery for craniopharyngioma.

**Case:** The male patient had presented with proteinuria and hematuria since childhood and was diagnosed with X-linked Alport syndrome by genetic testing at the age of 12 years. At 11 years of age, he underwent total hypophysectomy for craniopharyngioma and subsequently received hormone replacement therapy, including intranasal DDAVP, for panhypopituitarism. His renal function gradually deteriorated, and he underwent preemptive kidney transplantation at the age of 22 years. Before transplantation, his urine output was maintained at 1.5–2 L/day with intranasal DDAVP. During surgery, DDAVP was withheld to facilitate evaluation of the initial urine output from the graft. After transplantation, marked polyuria developed, and continuous intravenous infusion of AVP was initiated with careful monitoring of urine output and serum sodium levels. Although transient hypernatremia occurred, both urine output and electrolyte levels stabilized after resumption of AVP infusion. On postoperative day 4, when the patient was able to perceive thirst, treatment was switched back to intranasal DDAVP. Urine output stabilized at approximately 2 L/day, and the patient was discharged without complications. At 6 months after transplantation, graft function and electrolyte balance remain well controlled.

**Conclusions:** Reports of kidney transplantation in patients with CDI are extremely limited. In previously reported cases, CDI was diagnosed after transplantation due to postoperative polyuria, and our case appears to be the first in which transplantation was performed in a recipient already receiving DDAVP therapy for CDI. In



this case, withholding DDAVP during surgery enabled evaluation of the initial urine output from the graft, and early postoperative management with short-acting AVP infusion allowed strict control of urine output and electrolyte balance, resulting in a safe perioperative course.

**Points of discussion:** Does discontinuation of DDAVP pose any risk in patients with CDI undergoing kidney transplantation?

**Keywords:** central diabetes insipidus (CDI), Alport syndrome, kidney transplantation

## **The 22<sup>nd</sup> Korea-China-Japan Pediatric Nephrology Seminar 2026**

---

Publisher Joo Hoon Lee

Published by Korean Society of Pediatric Nephrology

Printed by DAON Convention

240, Gimpohangang 1-ro, Gimpo-si, Gyeonggi-do, Republic of Korea

Tel: +82-31-981-2764 Fax: +82-31-981-2765, E-mail: daonics@naver.com

---